Imaging Procedure Manual

Flexion Therapeutics FX006-2018-015:

A Randomized, Double-blind, Placebo-controlled, Parallel-group Study to Evaluate the Efficacy and Safety of FX006 in Patients with Hip Osteoarthritis

Radiography of the Hip

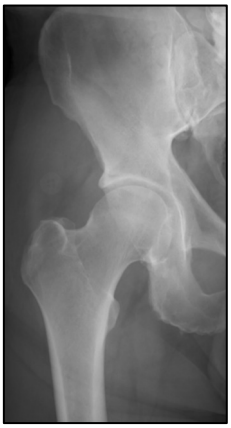



Version	1.0	**Date**	14-NOV-2018

This imaging manual has been reviewed and approved for use by:

Name / Title	***Signature***	***Date***
Charles Peterfy Chief Executive Officer Spire Sciences, Inc.		20-Nov-2018
Lorena Prekulaj Clinical Trial Manager Flexion Therapeutics, Inc.		03-Dec-2018

Table of Contents

1. Study Objectives and Imaging Needs

The primary objective of this phase 3 multi-center, randomized, double-blind, placebo-controlled, parallel-group study is to assess the effect of a single intra-articular (IA) injection of FX006 32 mg in patients with symptomatic osteoarthritis (OA) of the hip. The study population will consist of adults who are 40-80 years of age with symptomatic OA of the hip. Subjects will all have moderate to severe hip pain, but will be ambulatory and otherwise in good health. Candidate subjects will receive anterior-posterior (AP) and oblique radiographs of the index hip at screening, and if the radiographic criteria are met and the subjects meet all other study entry criteria, the subjects will proceed into the trial.

Radiographs will be assessed centrally by Spire for the absence of atrophic OA, osteonecrosis or subchondral fracture, and using Kellgren-Lawrence grading, for the presence of osteophytes and definite narrowing of the joint space (Kellgren-Lawrence grades 2 or 3) but not end-stage disease (Kellgren-Lawrence grade 4). Subjects who pass radiographic screening and meet all other eligibility criteria will be enrolled in the study and receive follow-up radiography of the index hip at Weeks 12 and end of study (Week 24 – 36 depending on timing of the second injection) or at an unscheduled visit for patients that discontinue the study early. This manual outlines the radiographic procedure for this study.

In contrast to clinical, single-center imaging, which is aimed at answering questions about managing individual patients, imaging for multi-center clinical trials requires the images to support research questions about large groups of subjects, and must be able to be pooled from multiple clinical sites with as little technical variation as possible despite differences in imaging equipment and local practice patterns. Further, the image quality must support quantitative measurements performed centrally rather than feature-based subjective readings done locally. The imaging protocols in this manual have been designed to meet these special needs, and may thus differ slightly from those used in your daily clinical practice. Please rest assured, however, that every effort has been made to keep the examinations as short and simple as possible and to minimize any burden on study subjects and disruption to your local routine.

In addition to this manual covering image acquisition technique, your site's designated image upload contacts (study coordinators and/or imaging technologists) will receive a separate document containing image upload instructions from AG Mednet. Please contact Spire Sciences if you have questions.

Submitting Images or Other Logistics:
Peter Countryman, Scientific Director, and project team:
PM-FX006-2018-015@spiresciences.com, Phone: +1.510.915.0915

Image Acquisition or Questions Regarding Repeat Requests:
Spire Sciences' MRI Quality Specialists:
QC-FX006-2018-015@spiresciences.com, Phone: +1.202.41-SPIRE (+1.202.417.7473)

2. Site Qualification

Qualification of your site to participate in this study will consist of your site's study technologists reviewing this manual and a brief web-based training video on the radiographic technique and how to submit images to Spire Sciences. This will be followed by a short quiz to confirm the technologists' understanding of key aspects of the procedure. Spire Sciences' Image Quality Control Specialist will be available to help by phone if needed. A minimum of two technologists for each site should be trained, in order to ensure backup.

Once the above steps have been completed, Spire Sciences will send a notice of qualification to your site's PI, study coordinator, imaging technologists and Flexion. This final step need not happen before your site's clinical SIV, but it must occur before any subjects are scheduled for radiography.

All technologists who perform imaging for this study must complete the training outlined above

3. Radiography Goals and Techniques

Radiography of the hip for clinical trials is similar to conventional radiography in clinical practice but with a greater focus on patient positioning and beam centering. In this study, two views of the target hip alone will be acquired at screening and each subsequent visit. The two views are 1) standing, frontal (AP) and 2) standing oblique (false profile of Lequesne).

The Fixed Flexion Frame

The Fixed Flexion Frame (Fig. 1) is designed to provide optimal, reproducible internal rotation of the hip for diagnosing and grading OA.



Figure 1. The Fixed Flexion Frame positioning device.

Standing AP View

- Prior to the examination, the Fixed Flexion Frame is placed on the floor, or suitably large platform, so that the detector or reclining table top of the radiographic system rests flush against it.
- The subject is positioned standing on the frame facing the X-ray camera. The entire medial aspect of each foot should be in contact with the V-shaped guide on the frame's base, with the heals touching the back wall of the frame. This internally rotates the hip reproducibly to allow accurate longitudinal assessments of change in joint-space width (JSN).
- Check distance from anterior superior iliac spines (ASIS) to table top on each side to be sure that pelvis is not rotated.
- The X-ray beam is centered on the femoral head of the index hip (Fig. 2), perpendicular and about 2 inches (5 cm) inferior to ASIS and 2 inches (5 cm) superior to the level of the pubic symphysis in average-sized subjects. *Do not center between the two hips.*
- Make sure that right-left markers and labels are correctly in place.
- Make sure that appropriate shielding is used, but ensure that it doesn't obscure the hip, so as to avoid repeats.
- Collimate to the imaging plate or flat panel detector, ensuring that the correct right-left marker is included in the view.
- Acquire a single AP exposure of only the index hip using the parameters below. *Although both hips are positioned on the frame, only one hip is radiographed.*

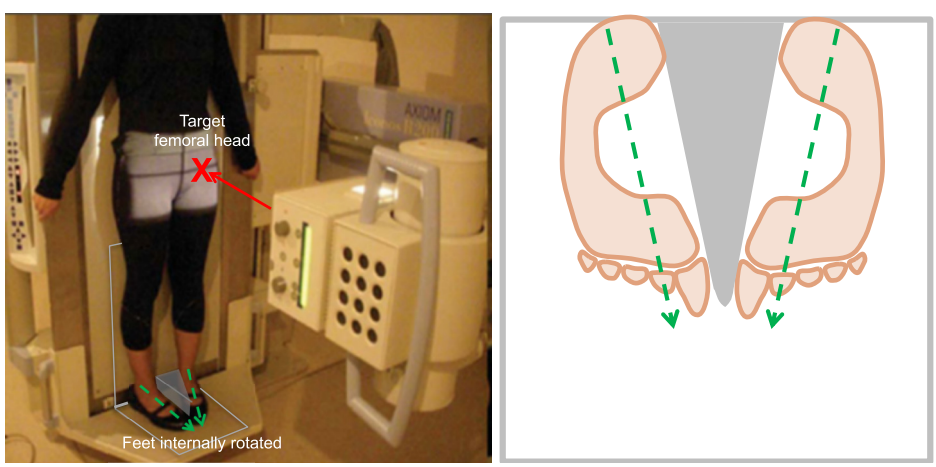

A. B.

Figure 2. Standing AP view. Subject stands on Fixed Flexion Frame facing X-ray tube with the feet internally rotated along the V-shaped guide on the floor of the frame (B) and the heels touching the back wall of the frame. The X-ray beam is centered on the index hip (A).

Standing Oblique (False Profile of Lequesne) View

- The subject is positioned standing on the frame obliquely facing the X-ray camera. The line between the patient's shoulders must be angled at 65º and the foot at the side of interest must be parallel to the back wall of the frame (Fig. 2.). The anterior aspect of this foot may extend beyond the frame.
- The perpendicular X-ray beam is centered on the femoral head of the index hip (Fig. 3).
- Make sure that right-left markers and labels are correctly in place.
- Make sure that appropriate shielding is used, but ensure that it doesn't obscure the hip, so as to avoid repeats.
- Collimate to the imaging plate or flat panel detector, ensuring that the correct right-left marker is included in the view.
- Acquire a single AP exposure of only the index hip using the parameters below. *Although both hips are positioned on the frame, only one hip is radiographed.*

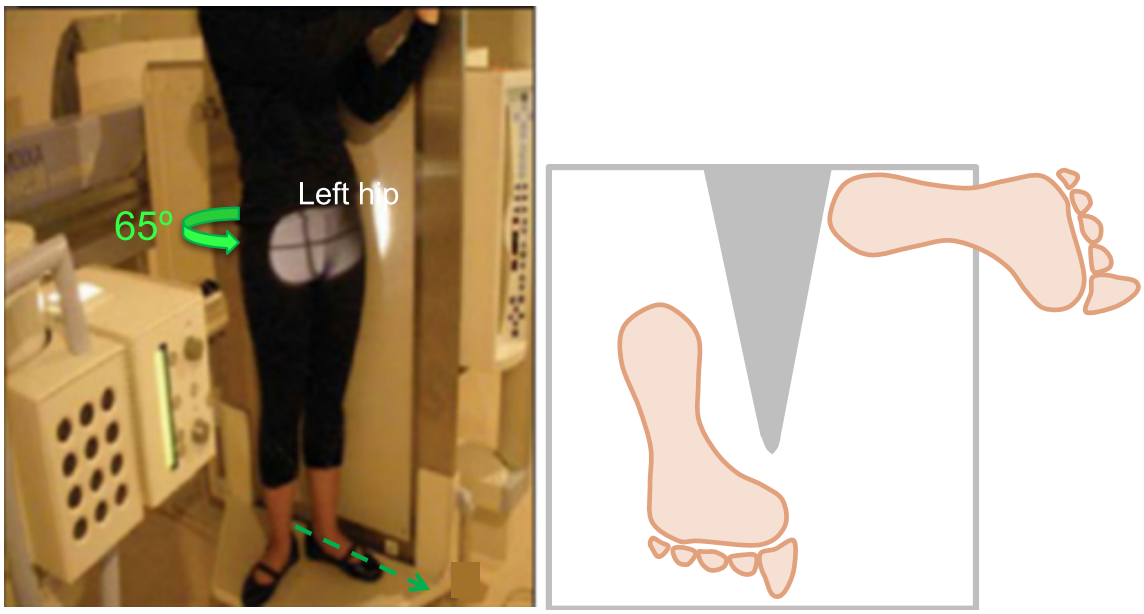

A. B.

Figure 2. Standing oblique (false profile of Lequesne) view. Subject stands on Fixed Flexion Frame facing X-ray tube turned 65º towards the hip of interest, in this example the left hip (A), with the ipsilateral foot parallel to posterior wall of the frame and detector (B).

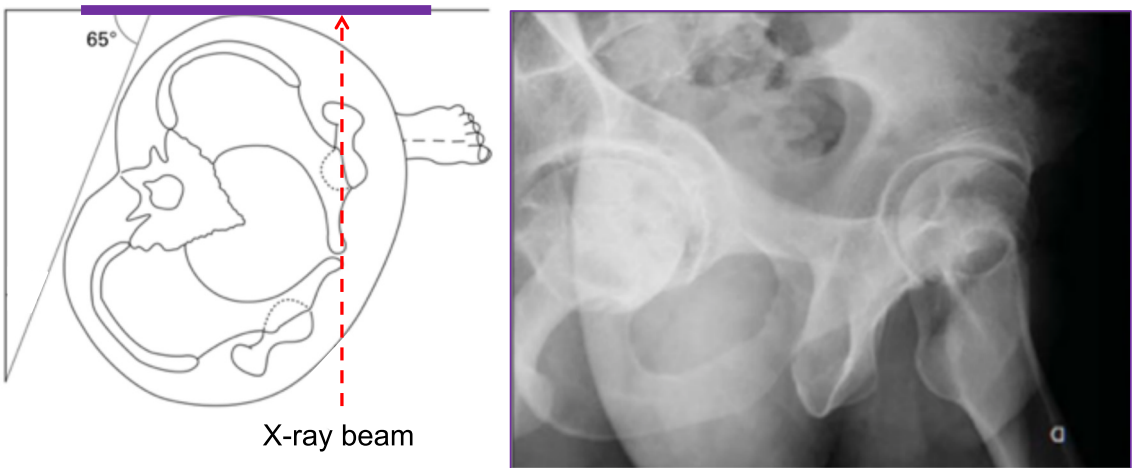

A. B.

Figure 3. Standing oblique (false profile of Lequesne) view. With the subject turned 65º towards the index hip, the parallel X-ray beam is centered on the femoral head (A). The resulting image should project the two hips the diameter of a femoral head apart from each other (B).

Radiographic Parameters

Scatter control	Bucky – *recommended*
Focus-Film Distance (FFD)	40 in – 47 in (100 cm – 120 cm) *Keep consistent*
Plate/detector size	11 in x 14 in (28 cm x 36 cm)
mA	*Dependent on system*
kVp	65 kVp – 72 kVp
Focal Spot	Small
Annotation	Right/Left radio-opaque markers *Do not include patient names or other private info in pixel data*
Beam centering	Index hip
Tube angulation	Parallel
Beam collimation	Collimate to imaging plate or flat panel detector. *Include entire acetabulum, 4 in (10 cm) of proximal femur, and R/L marker*
Pixel spacing	0.14 mm – 0.20 mm
Bit depth	10 bit –12 bit

4. Submitting Images to Spire Sciences

Images will be submitted to Spire Sciences via a third party image upload network, called AG Mednet. You should have received a copy of the AG Mednet Image Transfer manual for this

study, with detailed instructions for establishing an account and uploading images for this study. When uploading the images:

- Submit only original CR or DX images; no jpegs or secondary-capture images
- Always use the correct 3-digit site number for all images you upload. Do not use a made-up site number.
- Only one hip – the index hip – should be imaged and submitted.

Please submit your images to Spire Sciences on the same day that the images were acquired.

5. Image Quality Control

When images are received by Spire Sciences, they will be checked to ensure that they comply with the imaging protocol and provide adequate graphic quality to support Kellgren-Lawrence grading and accurate assessment of JSN.

Key Radiography Quality Goals

1. Adequate coverage of target hip and R-L markers
2. Adequate pixel spacing (resolution)
3. High image clarity and sharpness (for cortical bone)
4. Absence of artifacts
5. Good, reproducible projection of the joint space

Based on these checks, Spire Science's radiology team will designate each image as accepted or rejected, in three categories:

- "Yes" (fully adequate image quality; no repeat requested)
- "No, Try to Read" (image quality not optimal, but no repeat requested)
- "No, Unreadable" (image quality inadequate to support reading; repeat required)

Once the image has been checked for quality, you will receive a copy of the Flexion FX006-2018-015 Image Quality Report within one business day after image receipt by Spire Sciences to file in your study binder. If there are suggestions on how to improve your site's imaging quality, they will be noted in the comments of this form. If at any time you have questions regarding image acquisition for this study, please contact the lead technologist at Spire Sciences that will be assisting your site.

Spire Sciences Image Quality Report

Study PROTOCOL	Subject ID 01.001
Visit Week	Modality MR
Date of Exam 2014-02-13	
Image QC Performed by: David White	Date Image QC Performed 2014-02-13 13:46:15 PST
Was Image Quality Acceptable? Yes	ReportDate 13 Feb 2014, 21:46:49 UTC
Comments	

When images are rejected due to insufficient quality, the Image Quality Form result will be checked "**No, Unreadable**." This will indicate that the images must be repeated. If this occurs, please bring the patient back for repeat imaging as soon as possible. Once the repeat images are acquired, the same procedure should be used to submit the images, except that the box for "Repeat Exam" should be selected on the Transmittal Form.