Imaging Manual – Supplement

Centrexion CNTX-4975i-OA-304:

A Randomized, Double-blind, Placebo-controlled, 2-Injection 52-Week Study to Evaluate the Efficacy and Safety of Intraarticular Injections of CNTX-4975-05 in Subjects with Chronic, Moderate-to-severe Osteoarthritis Knee Pain

Kellgren-Lawence Grading

Version	1.0	Date	27-AUG-2018

Table of Contents

1. Purpose of this Supplement

The primary objective of this phase 3 randomized, double-blind, placebo-controlled, two-injection, 52-week study is to evaluate the safety and efficacy of an initial injection (at Baseline) and a second injection (at Week 26) of 1.0 mg of CNTX-4975-05, compared to placebo, delivered intraarticularly to the index knee, in subjects with chronic, moderate-to-severe index knee pain from osteoarthritis (OA).

Candidate subjects will be screened for presence and severity of structural OA based on Kellgren-Lawrence grading of fixed-flexion radiographs of bilateral knees. Subjects who meet the radiographic criteria along with all other requirements for eligibility will be enrolled in CNTX-4975i-OA-304.

As in the phase 2 trial of CNTX-4975-05 (protocol 4975-OA-502), eligibility readings of these radiographs will be performed centrally by Spire Sciences. In 4975-OA-502, the screening failure rate was approximately 75%, primarily because of absence of definitive radiographic OA. In an effort to reduce the screening failure rate in CNTX-4975i-OA-304, the following outline of the Kellgren-Lawrence grading (KLG) method is provided as a supplement to the radiographic acquisition manual to help explain the radiographic criteria being sought in CNTX-4975i-OA-304.

2. Kellgren-Lawrence Grading of Knee Osteoarthritis

General Principles

The KLG method was developed in the 1950s, but it is still the most common radiographic instrument used to screen OA patients for clinical trials. The method is, however, limited in a number of ways. Firstly, it's a composite score that aggregates several features of OA, including osteophytes, joint-space narrowing (JSN), subarticular sclerosis and joint deformity (Fig. 1).

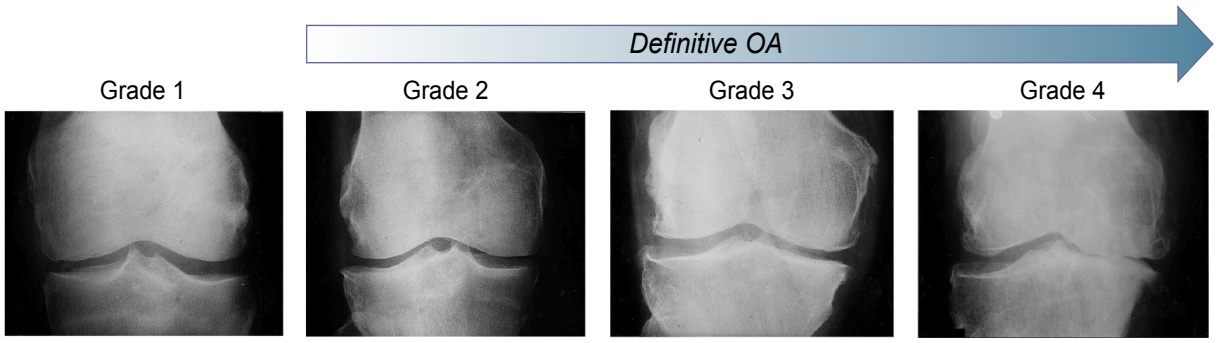

Figure 1. The Kellgren-Lawrence Atlas. Based on examples provided in an atlas (The Atlas of Standard Radiographs of Arthritis. *Rheumatology* 2005;44 Suppl 4:46-72), KLG includes the following four grades:

Grade1: Possible osteophytes, doubtful narrowing.
Grade 2: Definite osteophytes, possible narrowing

Grade 3: Moderate osteophytes, definite narrowing, some sclerosis, possible deformity
Grade 4: Large osteophytes, marked narrowing, severe sclerosis and definite deformity

The problem with this is that while the structural features included in KLG are linked, the linkage is not extremely tight, and the individual features can progress at different rates. Thus, one may observe severe JSN in knees with relatively small osteophytes, or mild JSN in knees with large osteophytes. Accordingly, the four grades depicted in the Atlas, intended to represent, equivocal, mild, moderate and severe OA, do not reflect all of the combinations of feature appearances one may encounter, and thus there remain questions as to which features to prioritize.

The current consensus is that the presence of osteophytes is the cardinal criterion for diagnosing OA. Therefore, in order to have definitive radiographic OA, a knee must have definitive osteophytes. There is some debate, however, over the pathophysiological significance of osteophytes and whether they actually represent an adaptive response of the joint to OA – that is to say, an attempt to stabilize joint laxity or diffuse excess load by enlarging the articulating surface area. Accordingly, change in osteophyte size is not considered a marker of disease progression in epidemiological studies and clinical trials of OA. Rather, once osteophytes are present, JSN is used to monitor disease progression and treatment response. In subsequent scoring methods, such as the Osteoarthritis Research Society International (OARSI) system, radiographic features are scored independently, with priority given to osteophytes and JSN. Subchondral sclerosis and bone attrition were also included but subordinated because of poor inter-reader reproducibility.

Applying these concepts to KLG, the lowest grade to include definitive osteophytes, and therefore to represent structural OA, is KLG 2. After that, the grades are driven primarily by the severity of JSN. Thus, osteophytes in the presence of a normal joint-space width or questionable JSN in either the medial or lateral tibiofemoral compartments should be considered KLG 2. Once one of these joint spaces becomes definitively narrowed, the knee becomes Grade 3, and severely narrowed joint-space (JSN >3/4 of the normal joint space width), is Grade 4. Osteophytes typically get larger and more numerous, and subchondral bone changes get more pronounced as the grade increases, but not always. The critical severity feature is JSN.

In this study, predominantly KLG 2 and KLG 3 knees are sought, but KLG 4 will be accepted for up to 20% of the cohort. Normal (KLG 0) and KLG 1 knees will be excluded. KLG 2 is thus the critical threshold for inclusion into the study. However, diagnosing KLG 2 accurately can be difficult. As mentioned earlier, the screening failure rate in the earlier phase 2 trial of CNTX-4975-05, protocol 4975-OA-502, was 75%. Many of these failures were KLG 0 knees thought by the submitting sites to be at least KLG 2. In a recent study of OA that included both radiography and MRI, a surprisingly large number of patients who were felt to be KLG 2 by the site, actually had no osteophytes or cartilage loss on MRI based on central review. This is despite the greater sensitivity and specificity of MRI for osteophytes and cartilage loss. These knees, therefore, did not have structural OA at all.

Pitfalls in Diagnosing Osteophytes

As noted above, the first step in radiographic diagnosis of OA is identifying the presence of marginal osteophytes. This in turn depends on proper radiographic technique, which externally rotates the knee sufficiently to allow unobstructed visualization of the margin of the medial femoral condyle. However, even with proper subject positioning, beam centering and beam angulation, there are a number of interpretative pitfalls to watch out for. The two most common mistakes are illustrated below.

Popliteus Groove in Lateral Femoral Condyle

A common error is mistaking the normal groove for the popliteus tendon along the margin of the lateral femoral condyle for an osteophyte. This groove can have a pronounced lip on it mimicking a bone spur (Fig. 2). Similarly, awareness of this normal variant can lead to under-diagnosis of true osteophytes in this location.

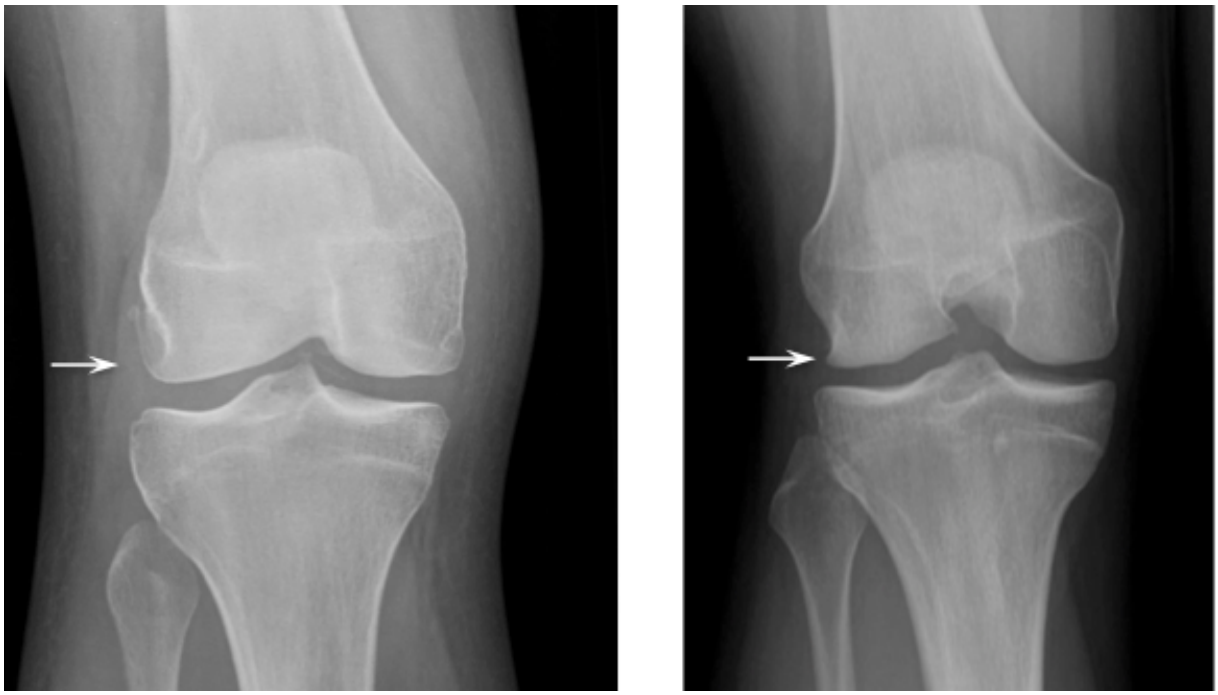

Figure 2. Pseudo-osteophyte lateral femur. Two different normal knees showing a prominent edge (arrows) to the groove for the popliteus tendon in the lateral femoral condyle that can sometimes mimic an osteophyte, thus lowering the specificity of radiographic diagnosis in this location.

Protruding Posterior Medial Femoral Condyle

When the knee is filmed in mild external rotation, the normal margin of the posterior portion of the medial femoral condyle projects medial to the rest of the femur, and can be mistaken for a large smooth osteophyte (Fig. 3). Similarly, a large smooth medial femoral osteophyte can be mistaken for the normal contour of the medial condyle in external rotation.

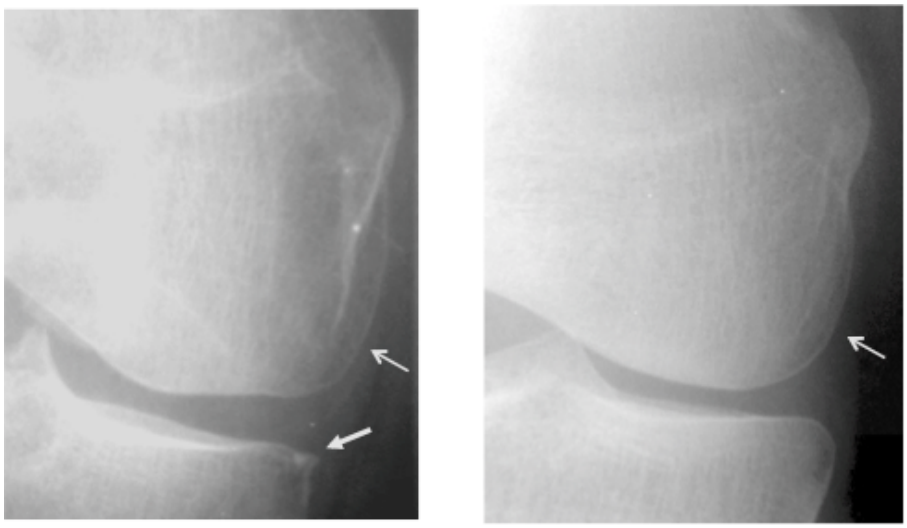

A. B.

Figure 3. Pseudo-osteophyte medial femur. Two different knees showing a prominent ridge along the medial femoral condyle suggestive of an osteophyte (open arrow). Skyline views of the knee on the left (A) confirmed this to be an osteophyte of the posterior medial femoral condyle. Note, this knee also has an osteophyte of the medial tibia (closed arrow), corroborating the diagnosis of OA. However, the feature (open arrow) in the image on the right (B) was just the normal margin of the medial femur.

Caution should be exercised when evaluating these two regions for osteophytes, especially if no other osteophytes or JSN are found to corroborate the diagnosis. These misinterpretations are the most common reasons for over-diagnosing KLG 2, but they can also result in under-diagnosis if interpretation is too conservative. Careful central reading can reduce over-diagnosis of KLG 2, but excessively high screening failure rates slow enrollment. On the other hand, when cases are under-diagnosed by the sites and thus not submitted to Spire Sciences for central assessment in the first place, subject enrollment also suffers. Accurate pre-screening of radiographs by the sites is therefore important to success of this study, and the reason behind this Supplement.

Pitfalls in Diagnosing JSN

Inadequate Flexion of the Knee

As noted above, correct evaluation of the severity of OA by KLG depends on sensitively and accurately identifying JSN. This in turn depends on proper fixed-flexion radiographic technique, which not only externally rotates the knee to visualize medial femoral osteophytes, but flexes the joint sufficiently to articulate the central-posterior region of the femoral surface where cartilage tends to thin first (Fig. 4).

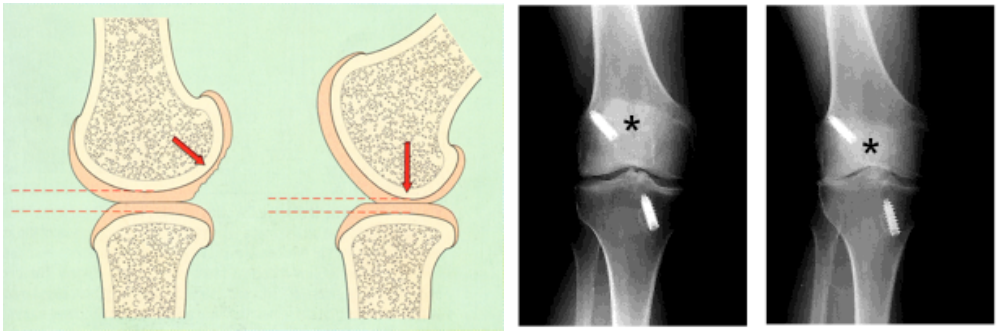

A. B. C.

Figure 4. Importance of flexion for detecting JSN. Cartilage loss in OA is heterogeneous, and most commonly begins in the center of the tibial plateau and the junction between the central and posterior surfaces of the femur. Accordingly, mild flexion of the knee is necessary for detecting early JSN (A). The knee in the radiograph shown on the left (B) was imaged in extension, and shows wide joint spaces. The same knee imaged in mild flexion (C), as indicated by the lower position of the patella (asterisk), shows severe JSN, with bone-on-bone contact. This example, further illustrates the critical importance of reproducing the degree of knee flexion on serially acquired radiographs for accurate determination of change in JSN. (From: Dieppe P, Peterfy CG, Watt I. Imaging evaluation of osteoarthritis. In: Klippel J, Dieppe P. Rheumatology. 2nd Edition. Mosby-Wolfe, London 1998: 8.4.1 - 8.4.10).

Inadequate flexion of the knee can thus under-estimate JSN and miscategorize a KLG 4 knee as KLG 3, leading to a higher proportion of KLG-4 subjects in the study than intended (≤20%). Such errors cannot be corrected by post-processing the images or centrally reading them, and so great care must be taken when acquiring the images.

Overcalling JSN can also be problematic, however, as it can unduly increase confidence that equivocal or simulated osteophytes are actually real, and thus lead to misclassification of normal knees as osteoarthritic. The most common causes of these are illustrated below.

Measuring Joint Space From Femur to Tibial Rims Not to Tibial Floor.

Because the medial tibial plateau is concave, when the X-ray beam is aligned parallel to the floor of the tibia, as approximated by 10° caudad beam angulation in the fixed-flexion technique used in this study (Fig. 4), the anterior and posterior rims of the plateau project above the floor of the plateau and thus appear closer to the opposing femoral surface (Fig. 5).

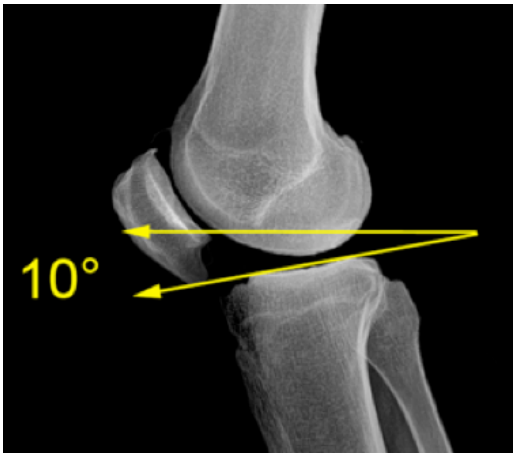

Figure 4. How the femoral and tibial articular surfaces project on fixed-flexion radiographs. Lateral knee radiograph (*not required for this study*) shows the concavity of the tibial plateau and the convexity of the femoral surface. Angulating the X-ray beam 10° caudad aligns it with the tibial floor, which results in the floor projecting below the tibial rims. The convex femoral surface, on the other hand, always projects as a solitary line above the tibia.

The tibial rims also appear much thinner than the floor does, because the rims pose only thin edges of bone in the way of the X-ray beam, whereas the tibial floor attenuates the X-ray beam along most of its length. The articular surface of the femur, on the other hand, is convex, and so no mater how the beam is aligned, the femoral surface will project as a solitary thin line above the tibia. Joint-space width is measured from the edge of the femur to the dense line of the floor of the tibia, which is the true articular surface of the tibia, not to the thin lines of the tibial rims that project above the floor, apparently closer to the femur (Fig. 5).

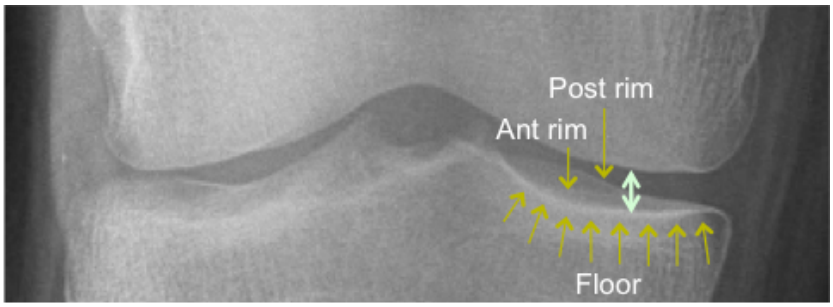

Figure 5. Optimal projection of the medial tibiofemoral joint space. The surface of the medial femur is convex, and thus projects as a sharp line regardless of the degree of flexion of the knee or angulation of the x-ray beam. The tibial plateau, however, is concave, and thus, the floor (row of arrows) of the plateau projects below the anterior and posterior rims (long arrows) when filmed with the X-ray beam aligned parallel to the tibial floor. Joint-space width is measured from the femoral surface to the floor of the tibia (two-sided arrow) not the rims of the tibia.

Mistaking the tibial rims for the actual articular surface of the tibia is a common reason for misdiagnosing JSN. When definitive osteophytes are present, this is not a major problem for the current study, as such an error would simply downgrade a misdiagnosed KLG 3 or 4 to KLG 2, which is still eligible. However, if pseudo-JSN is misdiagnosed as true JSN and it increases confidence in equivocal or pseudo-osteophytes as real, it can result in KLG 0 being

miscategorized as KLG 3 or even KLG 4 (Figs. 6 and 7). This happened several times in the phase 2 trial, 4975-OA-502, contributing to the high screen-failure rate of that study.

Figure 6. Pseudo-JSN. This case was submitted in a prior study (4975-OA-502) with suspected osteophytes and JSN. Both knees were imaged with inadequate flexion, as evidenced by the high position of patellas, the low position of fibular heads and the relative en-face projection of the medial tibial plateaus (compare with Figs. Because of this, the posterior tibial rims projected up to the articular cortex of the medial femur, mimicking bone-on-bone contact to the inexperienced eye. The denser tibial floor is much farther from the femur, and reveals the joint space actually to be quite wide. Regardless, there are no osteophytes in either knee, and so the KLG-2 threshold was not met on that basis, and the subject was not eligible for entry into the study. However, it is possible that the belief that there was high-grade JSN, and therefore OA, led the site to misinterpret some normal bone contours as osteophytes.

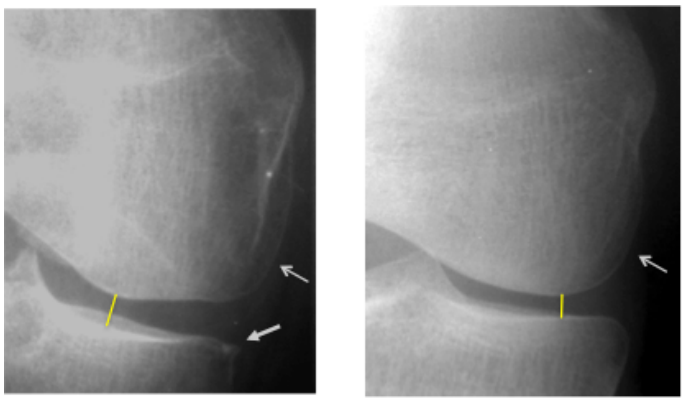

Figure 7. Pseudo-JSN. These are the same images as in Fig. 3. In this case the focus is on JSN. Note that the joint-space width (yellow line) in B is narrower than that in A, which is a knee with definitive OA. In absolute terms, however, the width in B is still within the range of normal, and without a prior image to confirm that this is true change, it cannot be assumed to be narrowed. If the bone protuberance along the margin of the femur (arrow) in B is actually an osteophyte, the probability of the apparent JSN being real would increase – and vice versa, of course. In this way, misdiagnoses in radiography can behave synergistically.

Normal Variability of Joint-space Width.

Not only is normal joint-space width highly variable in absolute terms, as illustrated in Fig. 7, there is also considerable variability in relative joint-space width between the medial and lateral tibiofemoral compartments. Often, the medial compartment is narrower than the lateral compartment, so this is not a reliable indication of cartilage loss (Figs 8 and 9). Provided both knees are flexed similarly and imaged properly, narrowing of a compartment in one knee

relative to the same compartment in other knee can be a valid sign of JSN. However, since the medial and lateral femoral condyles are connected, narrowing of one tibiofemoral compartment toggles the femur and widens the other. This can result in understating cartilage loss in the widened compartment.

Figure 8. Misdiagnosed JSN. This knee was misdiagnosed by the site as KLG 3, based on osteophytes of the medial femoral condyle and medial JSN. The investigator attributed JSN to the medial joint space width being less than half that of the lateral joint space. There are no femoral osteophytes evident, although an equivocal medial tibial osteophyte is present, but the medial joint space is within normal limits both in absolute and relative terms.

Figure 9. Normal variability of joint-space width. Both knees are from normal subjects, but show narrower joint space width in the medial compartment than in the lateral compartment.

3. Quiz Cases

The following examples are provided to test your KLG reading skills and to illustrate the points discussed above. Answers and explanations for each example are provided in the subsequent section.

Example 1.

Example 2.

Example 3.

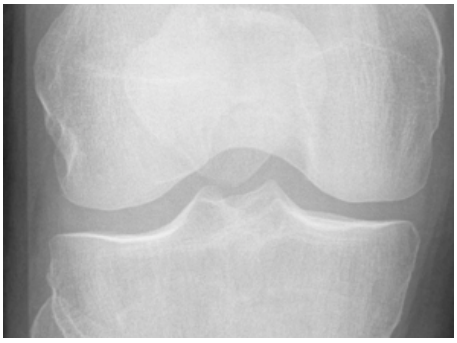

Example 4.

Example 5.

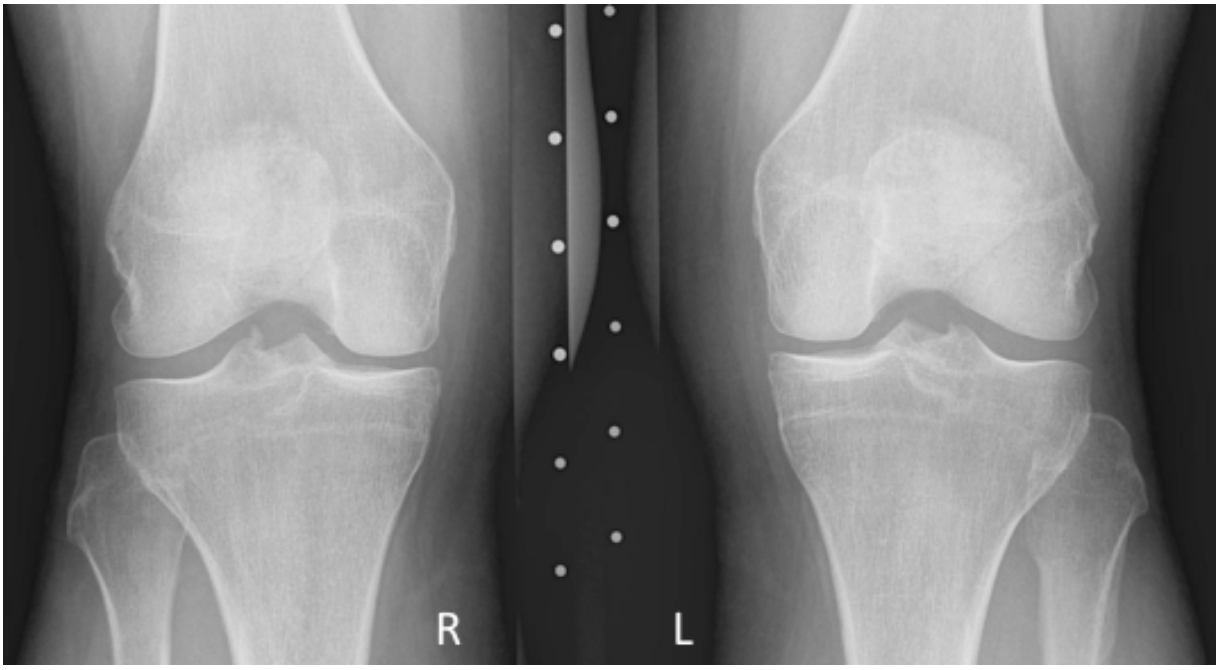

Example 6.

Example 7.

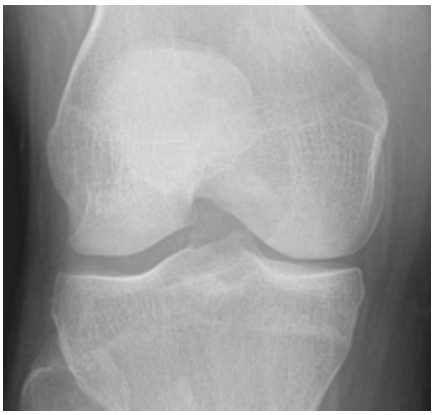

Example 8.

Example 9.

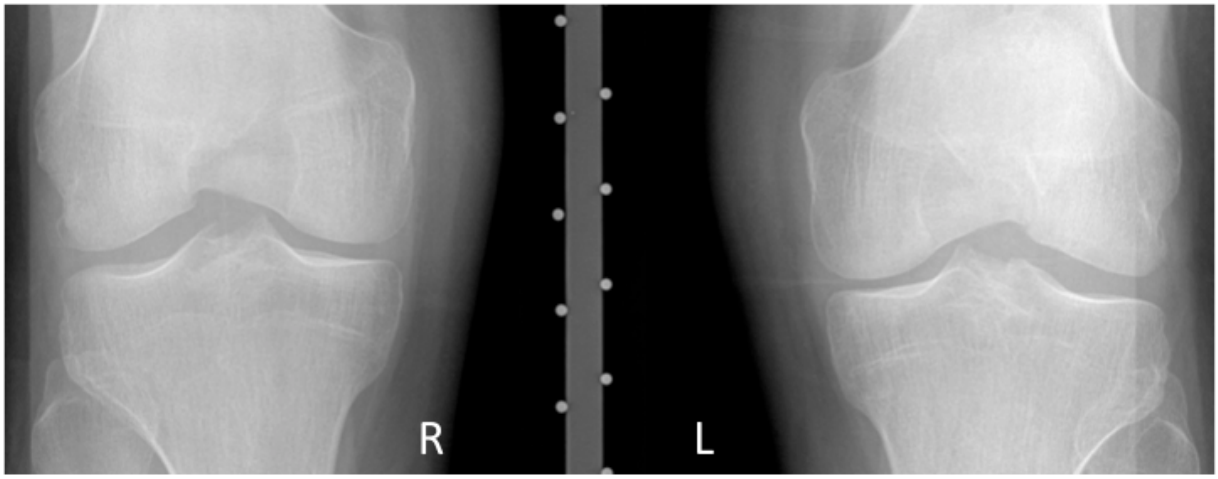

Example 10.

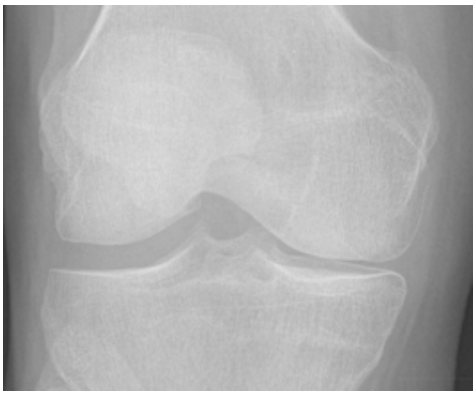

Example 11.

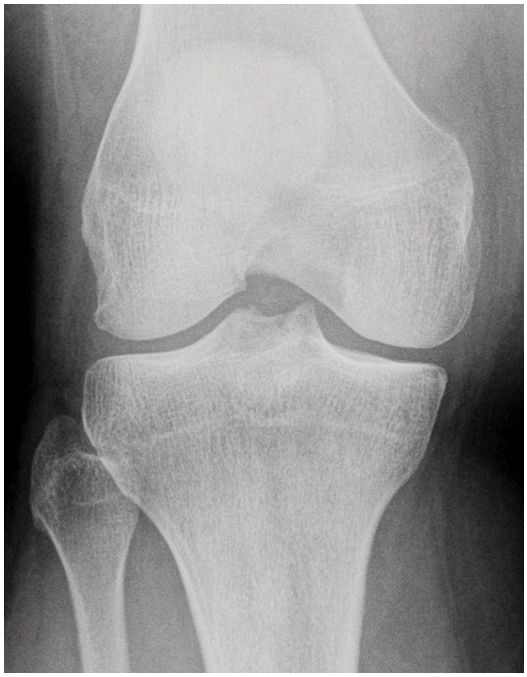

Example 12.

4. Answers to Quiz Cases

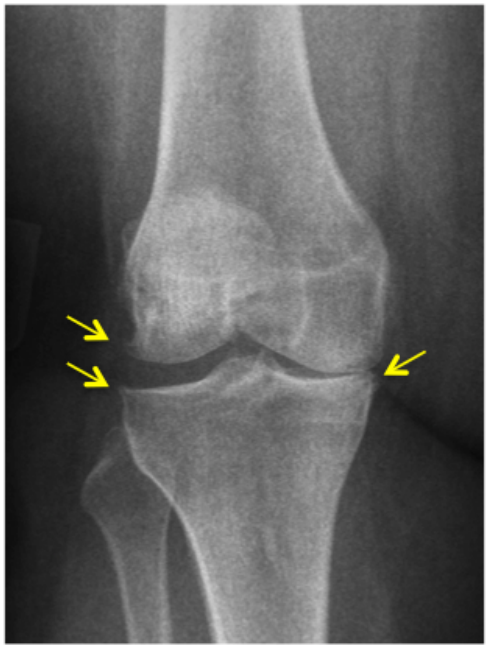

Example 1. KLG 4 with minimal osteophytes. This knee shows marked JSN medially with bone-on-bone contact of the two articular surfaces and mild subarticular sclerosis but only small osteophytes (arrows). Based on the KLG Atlas, marked JSN is found in KLG 4 (see Fig. 1), whereas small definitive osteophytes (arrows) are found in KLG 2. As noted above, however, when the severities of these two features fail to match, JSN severity should be given priority over osteophyte size as a marker of disease severity. Accordingly, this knee should be graded KLG 4.

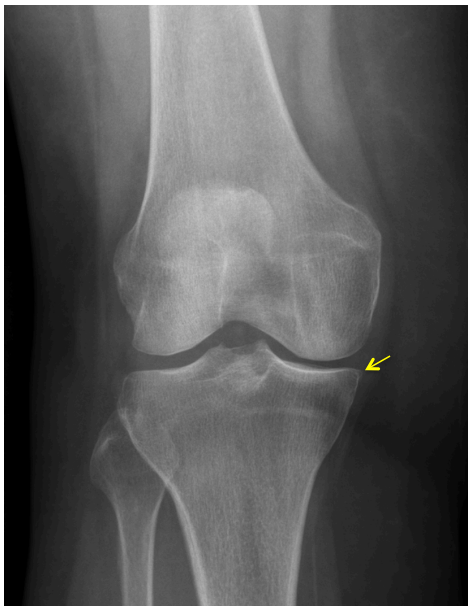

Example 2. KLG 2. There is a small but definitive osteophyte of the medial tibia (arrow) but no definitive JSN. Thus, this knee should be graded KLG 2.

Example 3. KLG 2 with apparently large osteophytes. This knee shows what appear to be large osteophytes medially and laterally, but normal joint-space widths. Based on the KLG Atlas, large osteophytes are found in KLG 4 (see Fig. 1), whereas normal joint-space width is found when KLG is ≤2. As noted above, however, when the severities of these two features fail to match, JSN should be given priority, and thus this knee should be graded KLG 2. On closer inspection, the apparently large medial femoral osteophyte is actually mostly the normal posterior condyle. It appears more prominent than usual because joint laxity in this case is associated with mild medial subluxation of the femur relative to the tibia. The lateral femoral osteophyte, while definitive, is also exaggerated because of the popliteal groove. The only other osteophytes are small spurs along the medial and lateral tibial margins. Thus, the osteophytes in this case are actually relatively small, in keeping with typical KLG 2.

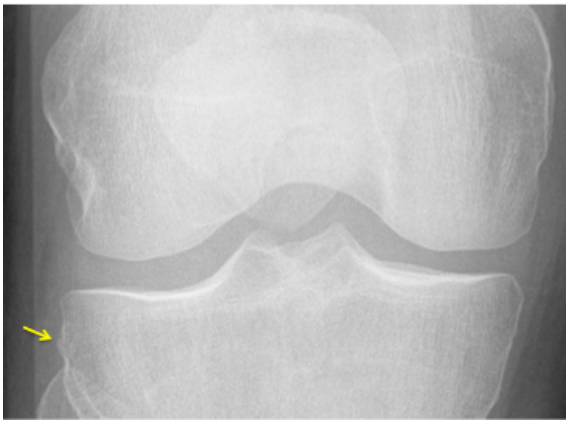

Example 4. KLG 0. This case was submitted as a suspected KLG 2, probably because of the small bone protuberance on the lateral tibia (arrow) and no JSN. However, the location of this protuberance is not along the margin of the tibal plateau, and therefore it does not qualify as a tibial osteophyte. No other osteophytes are seen, so this knee should be graded KLG 0.

Example 5. KLG 4. Classic example of KLG 4, with large medial osteophytes, severe JSN with bone-on-bone contact and subarticular bone changes, including deformity, with mild medial subluxation and what appears to be an osteochondral defect on the articular surface of the medial femoral condyle.

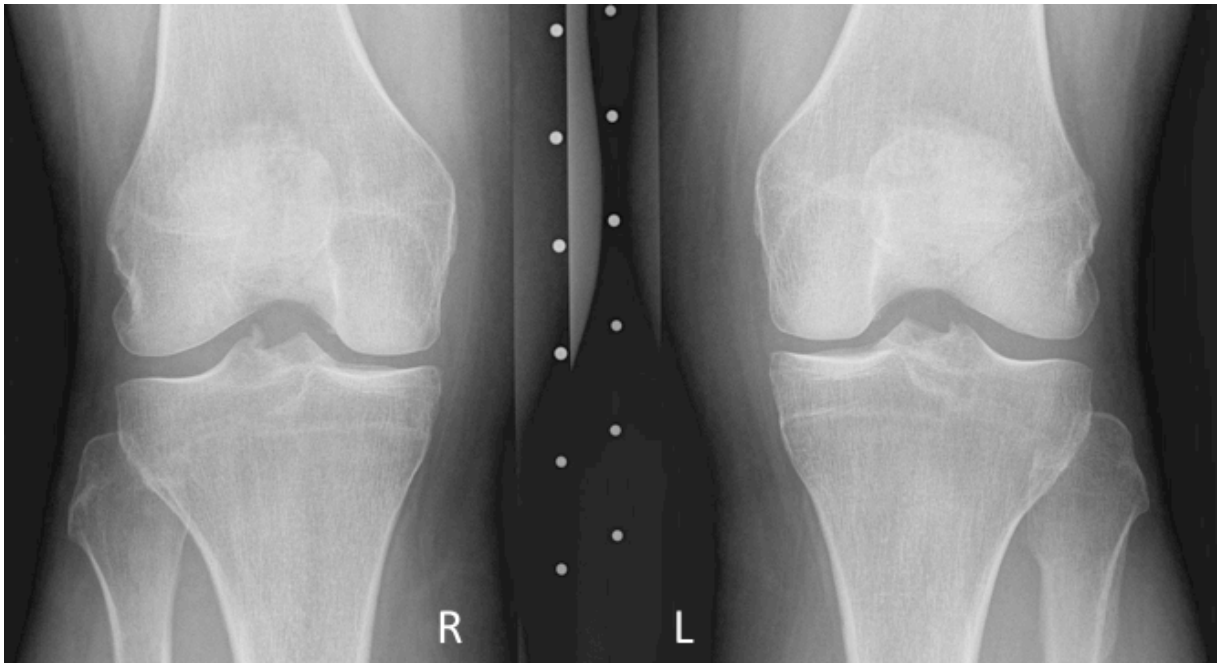

Example 6. KLG 1. This case was submitted as a suspected KLG 3. Bilateral knees show no definitive osteophytes, but on close inspection tiny, equivocal bone spurs are visible on both medial tibias. Assessing JSN on a single timepoint, such as this, is difficult because of the variability of normal joint-space width. Asymmetry of the joint-space widths between two knees can be a reliable indicator, but this depends on symmetrical application of radiographic technique. In this case, the joint spaces appear bilaterally symmetrical and normal in dimensions. The degree of knee flexion and rotation is identical bilaterally, as evidenced by similar superimposition of the anterior and posterior rims of the medial tibial plateaus and bilateral symmetry of other anatomical landmarks. Thus the technique was excellent. With only equivocal osteophytes and no JSN, both of these knees should be graded KLG 1.

Example 7. KLG 4. Classic KLG 4, with large bilateral osteophytes, marked JSN, subarticular sclerosis and deformity.

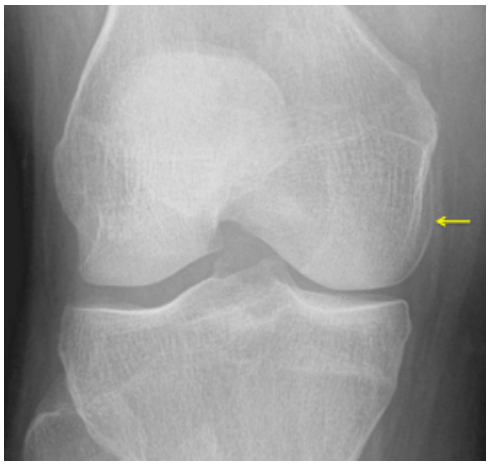

Example 8. KLG 0. External rotation of the knee projects the posterior margin of the medial femoral condyle (arrow) out beyond the rest of the femur. This normal contour is often mistaken for an osteophyte, but in this case it can be seen to be continuous with the remainder of the posterior femoral condyle indicating that it is a normal structure rather than an osteophyte. No other osteophytes are seen, and there is no JSN, so this knee is normal.

Example 9. KLG 3. This knee is a classic KLG 3. It shows moderate osteophytes medially and laterally, definite JSN medially, some sclerosis and possible deformity.

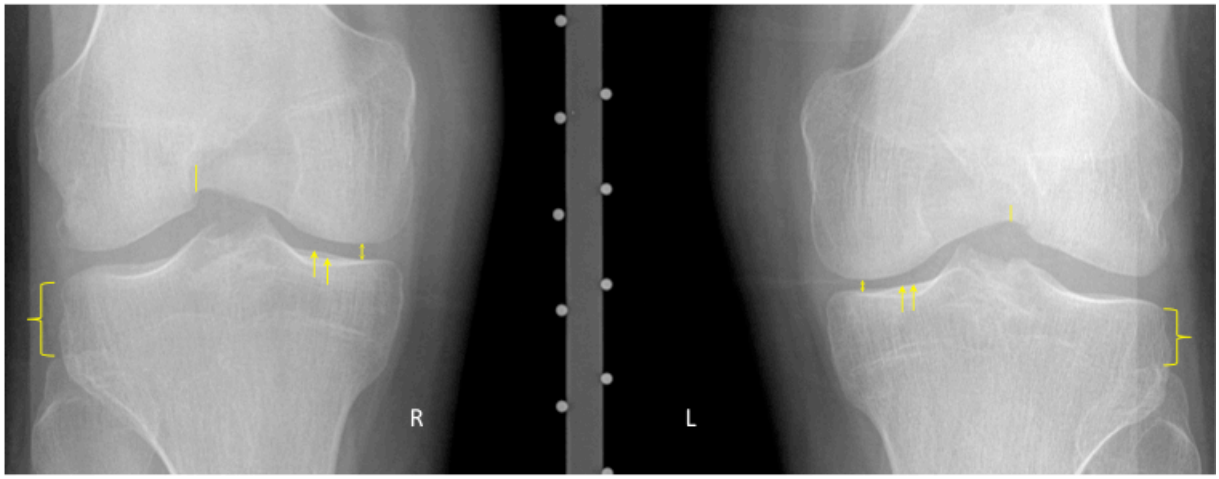

Example 10. Asymmetry of joint-space width. This radiograph shows bilateral knees submitted as suspected KLG 2 on the right and KLG 3 on the left, based on bilateral medial femoral osteophytes and medial JSN on the left. The prominent contours of the medial femurs are smooth and continuous with the margins of the normal posterior condyles, and thus normal. No other osteophytes are evident, thus these knees should not even be KLG 2. The medial tibiofemoral joint space on the left appears slightly narrower than that on the right, suggesting JSN (two-sided arrows). However, this may be due to asymmetry in the degree of flexion of the two knees. Based on the lower position of the left patella (lines), the greater superimposition of the left medial tibial rims (arrows) and the elevation of the left fibular head shortening the distance between it and the lateral tibial plateau (brackets), the left knee appears more flexed than the right knee does. Ideal fixed-flexion radiography results in bilateral symmetry of these anatomical landmarks.

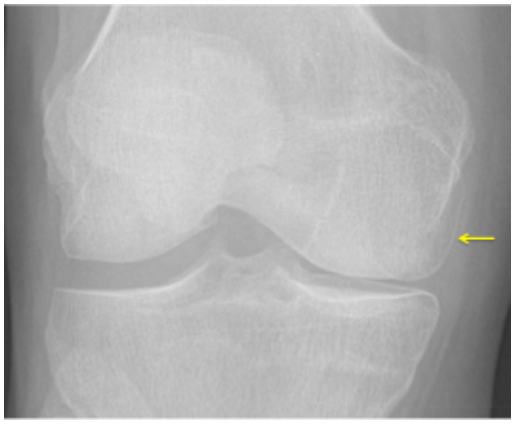

Example 11. KLG 0. There is a large bone protuberance along the medial margin of the medial femoral condyle (arrow), However, the contour of this protuberance is continuous with the rest of the posterior condyle of the medial femur, consistent with normal anatomy rather than an osteophyte. No other osteophytes are seen, and while the medial joint space is narrower than the lateral joint space, without prior images to confirm JSN, this must be assumed to be an normal variant. Thus, the knee is KLG 0.

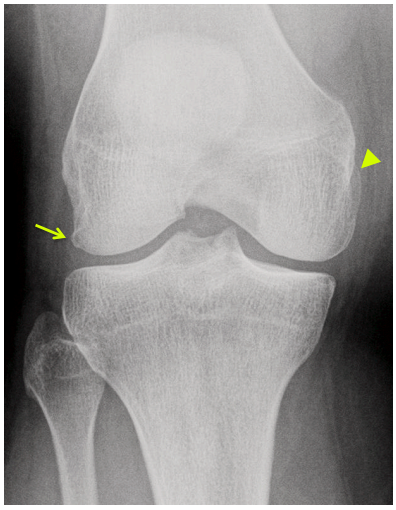

Figure 12. KLG 2. The lateral femoral margin is usually irregular because of the popliteus groove. Accordingly, the sensitivity for osteophytes in this location must be decreased in order to avoid an excessively high false positive rate. In this particular case, however, there is a sufficiently well-defined spur (arrow) to warrant a diagnosis of definitive osteophyte. A slightly protruding contour of the superior medial femoral condyle (arrow head) could be confused with an osteophyte, but in this case it is simply the normal condylar margin. The joint-space widths are within normal limits, so this knee is KLG 2.