SPIRE SCIENCES
Specialists in Imaging for Clinical Research

Imaging Procedure Manual

Flexion Therapeutics FX006-2017-014:

An Open-Label Study to Evaluate the Effect of the Administration of FX006 on Synovial Inflammation in Patients with Osteoarthritis of the Knee

Acquiring MRI of the Knee

© 2018 Spire Sciences, Inc.

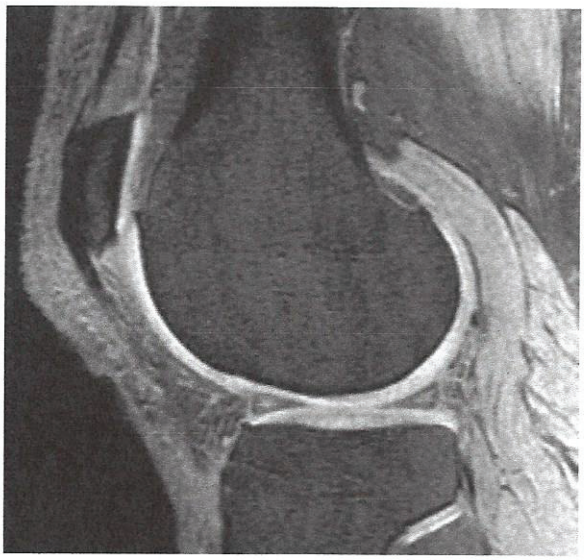

Version	1.0	**Date**	01-APR -2018

This imaging manual has been reviewed and approved for use by:

Name / Title	***Signature***	***Date***
Charles Peterfy Chief Executive Officer Spire Sciences, Inc.		01-APR-2018
Corrinne Lauze Clinical Trial Manager Flexion Therapeutics, Inc.		03-Apr-2018

© 2018 Spire Sciences, Inc. CONFIDENTIAL AND PROPRIETARY

Table of Contents

1. Study Objectives and Imaging Needs 4
2. Site Qualification 5
   1. Training Video and Quiz 5
   2. Test Scan 5
   3. Notice of Qualification 5
3. Performing the MRI 6
   MRI Scan Protocol 6
   Positioning the Subject for the Knee MRI 7
   Slice Prescription 7
4. Submitting Images to Spire Sciences 11
5. Image Quality Control 12

© 2018 Spire Sciences, Inc. CONFIDENTIAL AND PROPRIETARY

1. Study Objectives and Imaging Needs

The primary objective of this phase 3b open-label study is to assess the effect of a single intra-articular (IA) injection of FX006 32 mg to control inflammation as measured by a reduction in magnetic resonance imaging (MRI)-assessed synovial volume in patients with symptomatic osteoarthritis (OA) of the knee. Additional imaging endpoints include changes in bone, cartilage and meniscal morphology and contrast enhancement of tissues other than synovium. The study population will consist of adults who are at least 40 years of age with symptomatic OA of the knee. Subjects will all have moderate to severe knee pain, but will be ambulatory and otherwise in good health. Candidate subjects will receive a posterior-anterior (PA) radiograph of the index knee at screening, and if the radiographic criteria are met and the subjects meet all other study entry criteria as determined by the principal investigator, the subjects will proceed into the trial. Radiographs will initially be assessed locally at each site using Kellgren-Lawrence grading for the presence of osteophytes and possible or definite narrowing of the joint space (Kellgren-Lawrence grades 2 or 3) but not end-stage disease (Kellgren-Lawrence grade 4). Subjects who pass local screening will be further screened centrally for the presence of at least 2 mm medial tibiofemoral joint-space width. Subjects who meet all eligibility criteria will be enrolled in the study and receive MRI of the target knee -10 days to -1 day prior to baseline, and then at Weeks 6 and 24 to assess changes in inflammation and joint damage, as noted above. This manual outlines the MRI procedure for this study.

In contrast to clinical, single-center imaging, which is aimed at answering questions about managing individual patients, imaging for multi-center clinical trials requires the images to support research questions about large groups of subjects, and must be able to be pooled from multiple clinical sites with as little technical variation as possible despite differences in imaging equipment and local practice patterns. Further, the image quality must support quantitative measurements performed centrally rather than feature-based subjective readings done locally. The imaging protocols in this manual have been designed to meet these special needs, and may thus differ slightly from those used in your daily clinical practice. Please rest assured, however, that every effort has been made to keep the examinations as short and simple as possible and to minimize any burden on study subjects and disruption to your local routine.

In addition to this manual covering image acquisition technique, your site's designated image upload contacts (study coordinators and/or imaging technologists) will receive a separate document containing image upload instructions from AG Mednet. Please contact Spire Sciences if you have questions.

Submitting Images or Other Logistics:
Peter Countryman, Scientific Director, and project team:
PM-FX006-2017-014@spiresciences.com, Phone: +1.510.915.0915

Image Acquisition or Questions About Repeat Requests:
Spire Sciences' MRI Quality Specialists:

© 2018 Spire Sciences, Inc. CONFIDENTIAL AND PROPRIETARY

2. Site Qualification

Qualifying your site to participate in this study requires all technologists who will perform MRI at your facility to review this manual and a brief training video, successfully complete a short quiz and then submit a test scan as detailed below. A minimum of two technologists for each site should be trained, in order to ensure backup.

1. Training Video and Quiz

A brief, pre-recorded training presentation on how to acquire the images and transfer them to Spire Sciences will be provided. After reviewing the presentation, technologists must complete a post-training quiz to confirm their understanding of key aspects of the procedure. Upon successfully completing the quiz, a Training Completion Certificate will be issued by Spire Sciences, and the site will be asked to submit a test scan.

2. Test Scan

After completing training, each site will be instructed to create and save a copy of the study-specific scan prescription that can be recalled when a subject comes in for their exam. To ensure that this has been done properly and that the site is able to submit images to Spire Sciences through the AG Mednet network (see below), each site will be asked to provide a test scan using the study MRI protocol (without i.v. contrast). Ideally, a volunteer should be imaged, but if the site's local IRB prohibits this, a phantom (even a water bottle) can be used instead. If necessary, Spire Sciences' lead technologist can schedule a time to meet with your site's technologist over the phone while at the scanner console to help with this.

3. Notice of Qualification

Once the above steps have been completed, Spire Sciences will send a notice of qualification to your site's PI, study coordinator, imaging technologists and to Flexion. This final step need not happen before your site's clinical SIV, but it must occur before any subjects are scheduled for MRI.

All technologists who perform imaging for this study must complete the training outlined above.

© 2018 Spire Sciences, Inc. CONFIDENTIAL AND PROPRIETARY

3. Performing the MRI

MRI Scan Protocol

Only 1.5T or 3.0T whole-body MRI scanners should be used.

1. Sagittal 2D intermediate-weighted (IW) fast/turbo spin-echo (FSE/TSE) with fat saturation (FS)
2. Sagittal 3D T1-weighted (T1W) gradient-echo (SPGR/FLASH) with water excitation (WE) or FS
3. Sagittal 3D T1W gradient-echo (SPGR/FLASH) with WE or FS + i.v. gadolinium-based contrast agent (GD)

Scans 2 and 3 must be acquired using exactly the same acquisition sequence

The entire examination, together with the localizers and contrast injection, should take no longer than 40 minutes, but schedule a 60-min time slot in case repeat scans are necessary.

Table 1. Example MRI Pulse Sequence Parameters

	3-plane Localizer	2D TSE	3D FLASH	3D FLASH
Weighting	**T1W**	**Int**	**T1W**	**T1W**
Plane	3-plane	Sagittal	Sagittal	Sagittal
Fat Sat	No	Yes	WE	WE
Matrix (phase)	256	384	512	512
Matrix (frequency)	512	384	512	512
No. of slices	21	37	80	80
FOV (mm)	200	160	160	160
Slice thickness (mm)	5	3	1.5	1.5
Skip (mm)	1	0	0	0
Flip Angle (deg)	40	180	12	12
TE/TI (ms)	5	30	7.57	7.57
TR (ms)	10	3200	20	20
BW (Hz/pixel)	250	248	130	130
Chemical Shift (pixels)	1.8	0	0	0
NAV (NEX)	1	1	1	1
Echo train length	1	5	1	1
Phase Encode Axis	A/P, R/L	A/P	A/P	A/P
Options:		elliptical k-space filter and large FOV filter	elliptical scanning, elliptical k-space filter, larger FOV filter	elliptical scanning, elliptical k-space filter, larger FOV filter
Distance Factor (%)	50	0	0	0
Phase Oversampling	0	40	0	0
Slice Oversampling	0	0	0	0
Phase Resolution	50	70	100	100
Averaging Technique	Short Term	Short Term	Short Term	Short Term
Gradient Rise Time	Fast	Fast	Fast	Fast
RF Amplitude	Normal	Normal	Fast	Fast

© 2018 Spire Sciences, Inc. CONFIDENTIAL AND PROPRIETARY

Make sure flow comp is on and superior sat band is placed

3/5/2019
MES

Positioning the Subject for the Knee MRI

1. The knee coil base should be positioned on the table in alignment with the alignment marks on the table.
2. The knee coil should be used in only the L60 or R60 positions.
3. The knee pad should be inserted into the coil; this is the only pad that should be used beneath the knee such that slight flexion can be achieved in a consistent manner. The pad should be positioned such that it over hangs the coil edge by -1.5cm.
4. The target knee should be positioned in the coil such that the bottom of the patella is aligned with the center mark of the coil.
5. The leg should be in a relaxed, neutral position.
6. The foot should be vertical, with medial foot and the big toe perpendicular to the bed. The foot should be sandbagged to retain this position.
7. A positioning strap should be used secure both the coil and the contralateral knee. Pads should be used to ensure patient comfort.
8. The landmark position should be the center of the RF coil (align with marks) and should correspond to the bottom of the patella.

Slice Prescription

Localizer (3-plane)

This is a conventional three-plane localizer. Offsets for R60 and L60 coil positions should be programmed into the corresponding exam sequences.

Sagittal 2D IW TSE FS

This scan is primarily for quantifying the menisci and bone marrow edema. Therefore, homogeneous fat suppression is essential. Fat saturation usually fails in the vicinity of metallic implants, such as those used in anterior cruciate ligament repair, but also can fail around morphological irregularities, such as the patella. Please shim the magnet carefully, and use saline bags, e.g., just inferior to the patella, to minimize this problem.

This is a single oblique acquisition, oriented such that the sagittal slices are perpendicular to a line tangential to the posterior surfaces of the femoral condyles (Fig. 1). First, find the axial localizer slice with the largest cross-section through the condyles and the mid-joint sagittal and coronal localizer. The correct oblique angle is identified by first rotating and translating the imaging FOV such it is aligned with and touches both of the posterior condylar surfaces (oblique coronal). Then, without changing the angulation, select orthogonal slices (sagittal oblique). Finally, center the imaging FOV over the knee in the axial plane, ensure that it is centered in the coronal and sagittal planes as well, and using the sagittal localizer, move the imaging FOV superiorly so that the inferior limit of the FOV is slightly below the tibial epiphysis and the superior limit includes the entire suprapatellar recess of the synovial cavity. It is likely that the superior and inferior saturation bands will need to be moved outside the imaging FOV. Note that superior coverage may need to be adjusted on follow-up examinations to accommodate changes in distention of the suprapatellar recess by joint effusion and synovial tissue. Through-plane

© 2018 Spire Sciences, Inc. CONFIDENTIAL AND PROPRIETARY

coverage must include the medial and lateral margins of the femur and tibia and the entire synovial cavity of the knee. Skin-to-skin coverage is recommended to ensure this.

With very large knees, phase aliasing artifact may occur with this 160-mm FOV acquisition. Please avoid enlarging the FOV, as high spatial resolution is needed to ensure precise morphological measurements. Rather, adjust the imaging locations such that only regions of subcutaneous fat overlap (Fig. 4).

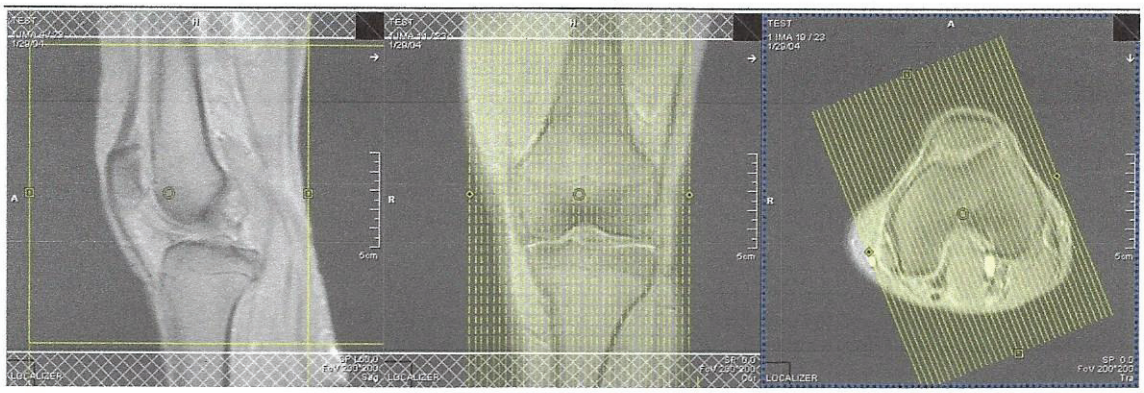

Figure 1. Slice prescription for sagittal 2D TSE IW FS.

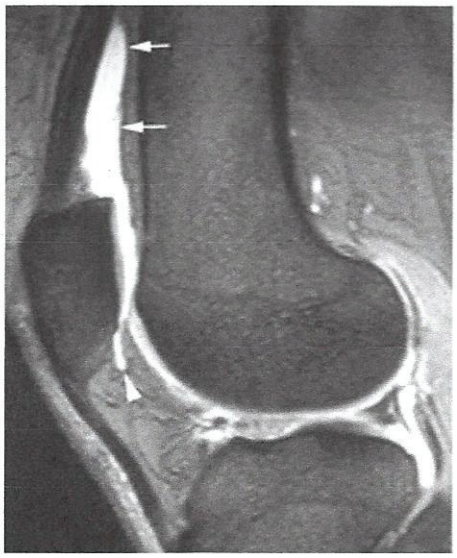

Figure 2. Essential anatomical coverage for sagittal 2D TSE IW FS. In-plane coverage must include not only the femoral and tibial epiphyses and the entire patella but also the entire suprapatellar recess of the synovial cavity (arrows). Note that synovial distention can vary from visit to visit.

© 2018 Spire Sciences, Inc. CONFIDENTIAL AND PROPRIETARY

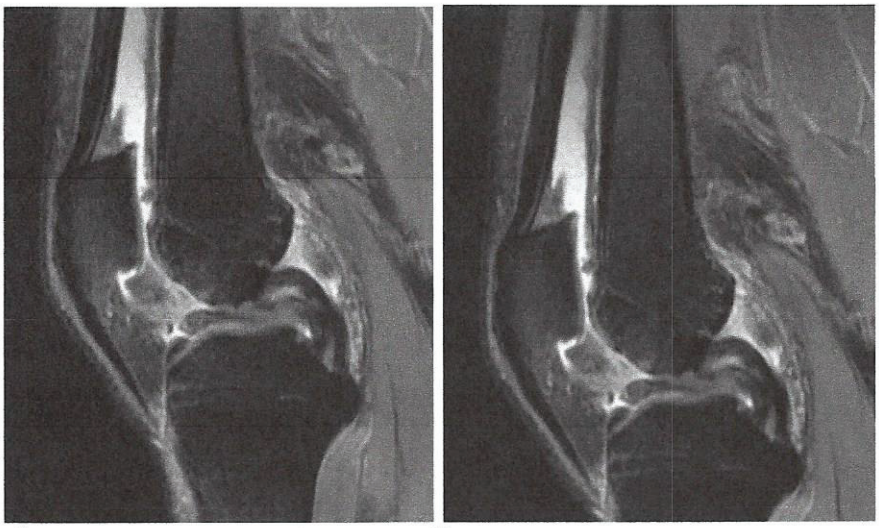

A. B.

Figure 3. Incomplete coverage of suprapatellar recess. Example A shows incomplete coverage of the superior extent of the suprapatellar recess distended by a large joint effusion. Shifting the FOV superiorly (B) captures the entire synovial recess while maintaining adequate coverage of the tibia.

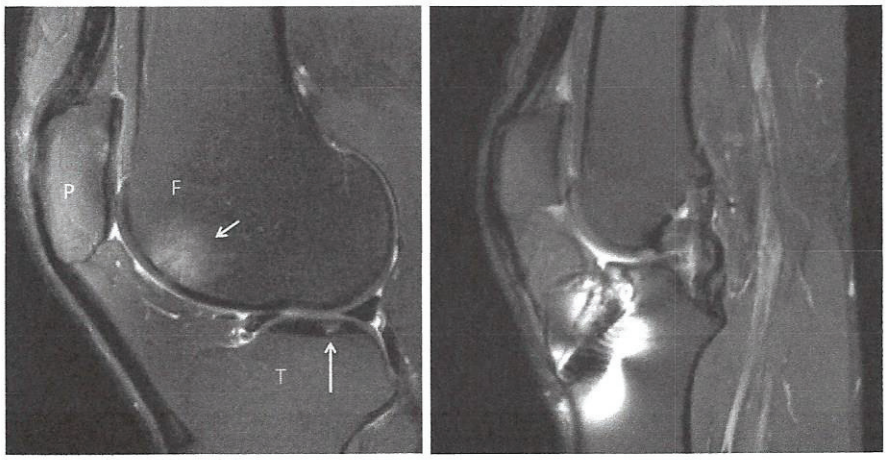

A. B.

Figure 4. Failed fat saturation. Sagittal 2D TSE IW FS scan A shows area of high signal intensity bone marrow edema (short arrow) in the anterior aspect of the lateral femoral condyle (F). Relatively high signal is also present in the patella (P). However, the signal in the patella defies natural anatomical boundaries and extends into the prepatellar and infrapatellar fat suggesting that it is related to failure of fat saturation rather than to pathology. Whether there is concurrent underlying bone marrow edema is difficult to determine because it also presents as increased signal intensity on this type of scan. Careful shimming of the magnet or placing a saline bag just inferior to the patella can help improve homogeneity of fat suppression. Focal high signal (long arrow) in the tibial (T) cartilage represents chondromalacia. Identifying this feature does not depend on fat suppression, but it, like GD enhancement, can be obscured if saturation heterogeneity is extreme enough to suppress water signal regionally. Example B shows severe fat-saturation failure adjacent to surgical hardware in a patient with previous cruciate ligament repair.

© 2018 Spire Sciences, Inc. CONFIDENTIAL AND PROPRIETARY

Figure 5. Pulsation artifacts. Sagittal 2D TSE IW FS scan shows pulsation artifacts from the popliteal artery behind the knee. Superior-inferior saturation bands can often mitigate this problem.

Sagittal 3D FLASH WE ± GD

These two scans are oriented similarly to the sagittal 2D TSE IW with FS, with sagittal slices perpendicular to a line tangential to the posterior surfaces of the femoral condyles, and are intended to support quantification of cartilage morphology and synovial enhancement.

First, find the axial localizer slice with the largest cross-section through the condyles and the mid-joint sagittal and coronal localizer. The correct oblique angle is identified by moving (rotating and translating) the 3D imaging FOV (box) such that its posterior limit just touches both of the posterior condylar surfaces. Then, without changing the angulation, center the box over the knee. Check the imaging FOV to ensure that it is centered in the coronal and sagittal planes, and adjust as necessary. Do not change the number of slices in the protocol, even for small knees.

After acquiring the scan without GD. Without retracting the MRI table or otherwise moving the subject, administer intravenous GD in a single bolus injection, and repeat the scan exactly as before without changing the slice prescription or any other pre-GD scan parameters.

The goal is to acquire the post-GD image with the same image windowing as that used in the pre-GD images. Manufacturers use different methods to achieve this, so check with the appropriate documentation – but ensure that the post-GD image is acquired using exactly the same windowing (image contrast) as that used for the pre-GD image.

© 2018 Spire Sciences, Inc. CONFIDENTIAL AND PROPRIETARY

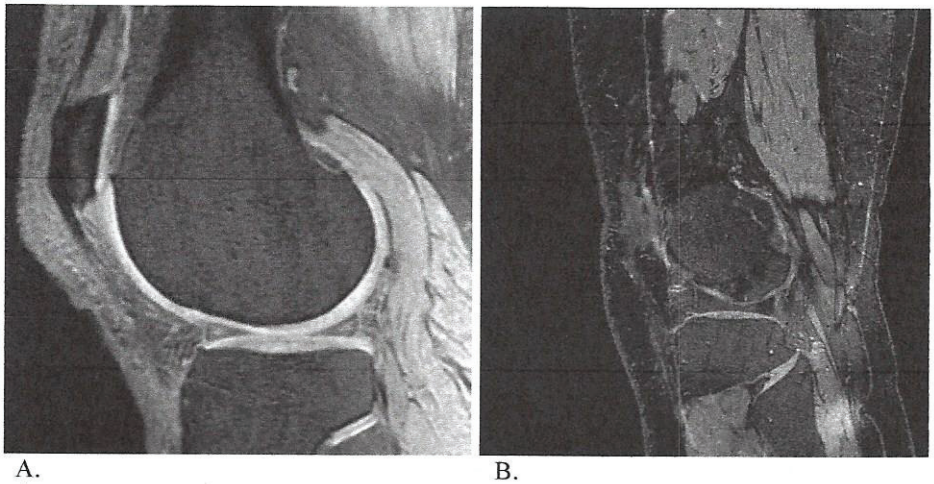

A. B.

Figure 6. Sagittal 3D T1W FLASH WE image quality. Example A shows good delineation of the cartilage along its entire length over each articular surface, including between the femoral cartilage and the infrapatellar fat pad and the posterior capsule. Fat suppression by WE is homogeneous and robust, and there is no signal drop off superiorly or inferiorly. No subject motion, vascular pulsation or wrap (aliasing) artifacts are present. No effusion or synovitis is present, but should it develop in the future, the FOV may have to be adjusted on follow-up scans. If there is a popliteal cyst, try to include it, but prioritize the suprapatellar recess. Example B shows the lateral-most slice of a 3D scan with incomplete through-plane coverage. Coverage should include the entire medial-lateral extent of the femur tibia and patella and the entire synovial cavity.

As previously mentioned, given the relatively small FOV needed in this study, aliasing may occur, especially in large knees. Aliasing artifacts are acceptable as long as no enhancing synovium or patellar, femoral, and tibial cartilage are obscured (Fig. 7).

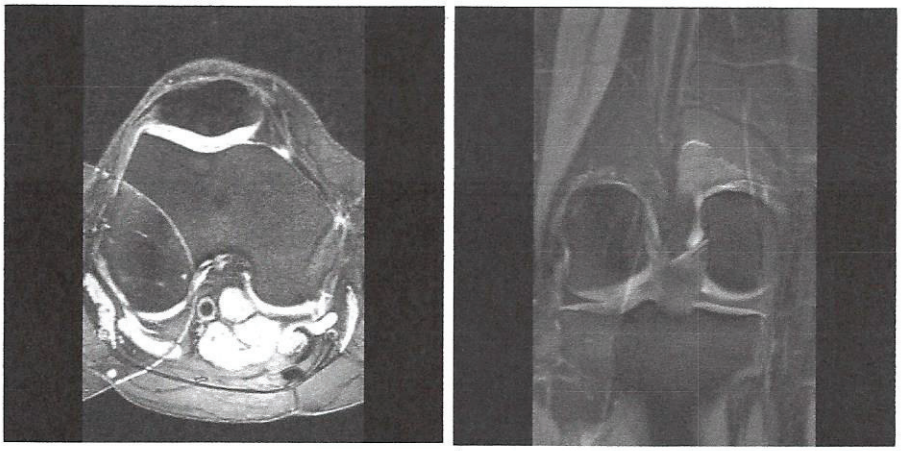

Figure 7. Aliasing artifact. 3D T1W FLASH WE scans show excessive aliasing obscuring portions of the articular cartilage and synovial cavity. *Axial and coronal planes are not part of the FX006-2017-014 MRI protocol, but are shown here to illustrate the image quality problem.*

4. Submitting Images to Spire Sciences

Images will be submitted to Spire Sciences via a third party image upload network, called AG Mednet. You should have received a copy of the AG Mednet Image Transfer manual for this

© 2018 Spire Sciences, Inc. CONFIDENTIAL AND PROPRIETARY

study, with detailed instructions for establishing an account and uploading images for this study. When uploading the images:

- Always use the correct 3-digit site number for all images you upload, even if you are sending test images. Do not use a made-up site number.
- If sending Test Data, use "1400" for the subject part of the "Site – Subject" identifier.
- The same knee – right or left - should be imaged at each visit of a subject.
- If a repeat exam has been requested by Spire for a particular visit, *e.g. Baseline*, the repeat image should be uploaded with the same visit label.

If there are errors or mismatches in subject IDs or other information submitted to Spire Sciences, a Data Clarification Form will be sent to you or your study coordinator to provide an audit trail for any corrections.

Please submit images to Spire Sciences on the same day that they were acquired.

5. Image Quality Control

When images are received by Spire Sciences, they will be checked to ensure that they comply with the imaging protocol, fully cover the anatomy required, and provide adequate graphic quality to support the assessments that will be performed. Follow-up images will be compared to those of prior visits to ensure adequate reproducibility.

To minimize variability, please use the same equipment for all serial examinations of a particular subject. If a significant change of hardware or software is anticipated at any time during the study, **contact Spire Sciences before this change occurs.**

Please also notify Spire Sciences of any changes in personnel or contact information, and if any new technologists join the study, they must complete training prior to imaging any subjects.

Key MRI Quality Goals

1. Complete coverage of the knee (in-plane and through-plane)
2. Correct voxel size (in-plane resolution, slice thickness)
3. High signal-to-noise ratio and signal homogeneity
4. Absence of artifacts obscuring any features of interest*
5. Comparable coverage and image quality on serial examinations

© 2018 Spire Sciences, Inc. CONFIDENTIAL AND PROPRIETARY

*Common artifacts include:

Aliasing	Aliasing can be tolerated as long as structures of interest are not obscured
Subject Motion	Usually limited by use of pads and sandbags, and by instructions to subject
Pulsation artifacts	Artifacts from the popliteal artery are often unavoidable, but can be minimized by properly placed saturation bands
Chemical Shift	Minimized by proper choice of band-width and frequency encode direction.
Fat Saturation Failure	Partial fat saturation failure is tolerable at the image periphery as long as the contrast of features of interest (e.g., cartilage and bone marrow edema) is not compromised
Metallic artifacts	May arise from implants and other metallic objects; acceptable if they do not obscure structures of interest

Based on these checks, Spire Science's radiology team will designate each image as accepted or rejected, in three categories:

- "Yes" (fully adequate image quality; no repeat requested)
- "No, Try to Read" (image quality not optimal, but no repeat requested)
- "No, Unreadable" (image quality inadequate to support reading; repeat required)

Once the image has been checked for quality, you will receive a copy of the Flexion FX006-2017-014 Image Quality Report within one business day after image receipt by Spire Sciences to file in your study binder. If there are suggestions on how to improve your site's imaging quality, they will be noted in the comments of this form. If at any time you have questions regarding image acquisition for this study, please contact the lead technologist at Spire Sciences that will be assisting your site.

© 2018 Spire Sciences, Inc. CONFIDENTIAL AND PROPRIETARY

Spire Sciences Image Quality Report

Study PROTOCOL	Subject ID 01.001
Visit Week	Modality MR
Date of Exam 2014-02-13	
Image QC Performed by: David White	Date Image QC Performed 2014-02-13 13:46:15 PST
Was Image Quality Acceptable? Yes	ReportDate 13 Feb 2014, 21:46:49 UTC
Comments	

When images are rejected due to insufficient quality, the Image Quality Form result will be checked "**No, Unreadable**," to indicate that the images must be repeated. If this occurs, it is important to bring the patient back for repeat imaging as soon as possible, so as to avoid biasing the study results. As soon as the repeat images are acquired, the same procedure should be used to submit the images, except that the box for "Repeat Exam" should be selected on the Transmittal Form.

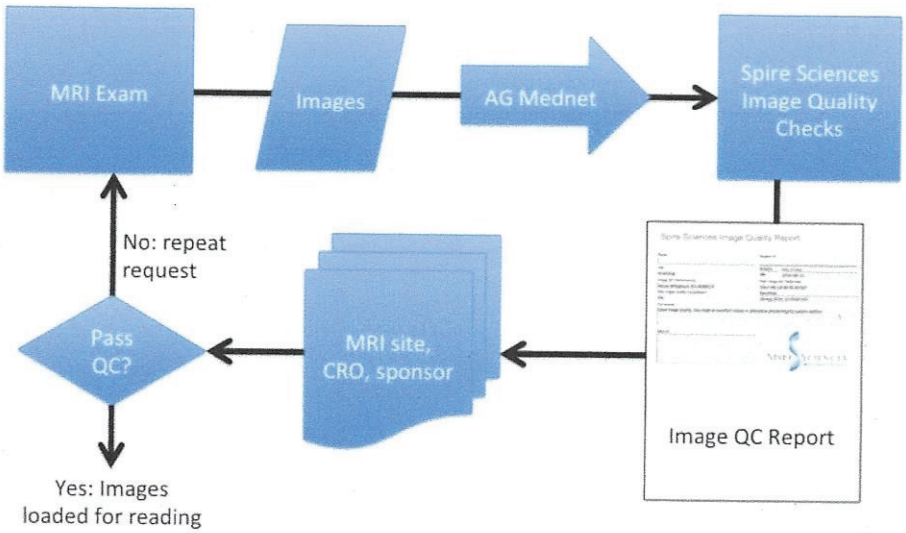

Figure 8. Image data flow. If images cannot support the analyses required, Spire Sciences will request a repeat examination in the Image QC Report.

© 2018 Spire Sciences, Inc. CONFIDENTIAL AND PROPRIETARY