

MEDICAL IMAGING SERVICES

ASTELLAS PHARMA GLOBAL DEVELOPMENT, INC.

Protocol 2693-CL-0302

A Phase 3, Randomized, Placebo-controlled, 12-week Double-blind Study, followed by a Non-Controlled Extension Treatment Period, to Assess the Efficacy and Safety of Fezolinetant in Women Suffering from Moderate to Severe Vasomotor Symptoms (Hot Flashes) Associated with Menopause

Image Acquisition Guidelines - Transvaginal Ultrasound (TVU)

PROPRIETARY STATEMENT: THIS IMAGE ACQUISITION GUIDELINE IS A PROPRIETARY DOCUMENT PROVIDED BY PAREXEL INFORMATICS IN SUPPORT OF THE ASTELLAS 2693-CL-0302 TRIAL. ALL MATERIAL CONTAINED HEREIN IS CONFIDENTIAL AND PROPRIETARY TO PAREXEL. **DO NOT DISTRIBUTE OR DUPLICATE.**

Project:	Astellas 2693-CL-0302/ PAREXEL 242903
Document File Name:	Image Acquisition Guidelines - Ultrasound
Document Revision:	v1.0
Version Date:	23-May-2019
Authors:	Elaine Collins RDMS, Heather Blank RDMS

Copyright Page

Copyright© 2019 PAREXEL International Corporation. All rights reserved.


The material presented in this document and contained herein is proprietary and confidential to PAREXEL International and its subsidiaries and is intended for PAREXEL employees and its clients use only. The material is to be used for the purpose for which it was delivered or made available to you subject to the terms and conditions (if any) of applicable licenses. Each User shall maintain the confidentiality of the material and shall not disclose, distribute, reproduce, or otherwise disseminate, in whole or part, any part of this document or the information contained herein to any third party, without the prior written permission of PAREXEL International. Any unauthorized use or disclosure of this document or the information contained herein, including any resale, reproduction, or any attempt to do so, is strictly prohibited.


Information in this document is subject to change without notice and supersedes all earlier versions for this product.

Document Approvals

Document Title: **Image Acquisition Guidelines - Ultrasound**
 Document Version: 1.0
 Project: **Astellas 2693-CL-0302/ PAREXEL 242903**

This document has completed a review and is understood and accepted by the following:

 28 MAY 2019
 Ingrid Gagainis Date
 Senior Clinical Study Manager
 Astellas Pharma Global Development, Inc.

 28 MAY 2019
 Christopher Lademacher, MD, PhD Date
 Executive Medical Director, Medical & Development
 Astellas Pharma Global Development, Inc.

PAREXEL internal signatures will be captured electronically through the PMED system.

Elaine Collins
 Associate Director, Scientific and Medical Services
 PAREXEL Informatics

Heather Blank
 Senior Scientist
 PAREXEL Informatics

Kate Francis
 Senior Project Manager
 PAREXEL Informatics

Document Revision History

Version	Date	Authors	Description
1.0	23-May-2019	Elaine Collins, Heather Blank	Initial release of document

TABLE OF CONTENTS

TABLE OF CONTENTS	4
INTRODUCTION	4
IMPORTANT NOTES.....	5
SONOGRAPHERS	5
MACHINE/OUTPUT FORMATS	6
BEST PRACTICES FOR OPTIMAL QUALITY ULTRASOUND IMAGING.....	6
IMAGE LABELING	8
RECOMMENDED IMAGE LABELS AND ACCEPTABLE ABBREVIATIONS.....	9
TRANSVAGINAL ULTRASOUND (TVU)	10
TVU – PREPARATION AND IMPORTANT REMINDERS	10
TVU - IMAGE VIEW REQUIREMENTS	11
TVU - REPRESENTATIVE IMAGES	11

For inquiries regarding these guidelines, please contact:

PAREXEL Informatics Medical Imaging Team 242903

Email: 242903-Imaging@parexel.com

INTRODUCTION

PAREXEL Informatics has developed these image acquisition guidelines for standardization of the study imaging components across radiology centers participating in the Astellas 2693-CL-0302 clinical trial. Required images for ultrasound are based on the guidelines from the American Institute of Ultrasound in Medicine (AIUM). Provided here are image acquisition guidelines for the following imaging modalities:

Imaging Modality	Imaging Schedule
Transvaginal Ultrasound (TVU)	<ul style="list-style-type: none"> Screening Visit 15/ Week 52 Early Withdrawal

Important Notes

- **Subject safety in relation to image acquisition is the responsibility of the Investigator sites.**
- Scheduled imaging for this study should be acquired in adherence to these guidelines. Imaging should remain as consistent as possible across all imaging visits for any given study subject.
- For participants in a study trial, there are occasions when more images may be required than what is standard in clinical practice. Please keep in mind that the independent reviewers only have access to the images provided and have no ability to view the subject in real time or to access subject history. Importantly, if the sonographer is unable to see the anatomy or the pathology, the independent reviewer will not be able to make a complete assessment.
- All confidential subject information must be de-identified prior to sending the data to PAREXEL. **The names of the subject and investigator site and any other information that can be used to identify the subject or investigator site must be removed from the images. Images for review should ONLY contain the Subject number.**
 - If subject name is a required field at your site, it is recommended to use the study subject number in this field
- **Images sent to PAREXEL shall be clear of any measurements to avoid biasing the independent reviewer.**
- Keep imaging data (including raw/original data) digitally archived for the remainder of the study. Digital images will be submitted via electronic transfer (eTransfer). **Electronic transfer is the preferred method of transmission.** All images should be submitted to PAREXEL no later than 3 business days following acquisition. If eTransfer cannot be used, please contact PAREXEL at 242903-Imaging@parexel.com
- Send ALL protocol specified images acquired to PAREXEL unless instructed otherwise by either Astellas or PAREXEL.

Sonographers

To minimize inter-observer variability and ensure consistent study imaging, **a maximum of two individual sonographers should be involved and dedicated to this study at each site. Ideally, the primary sonographer should perform at least 80% of all study scans, and a backup person is required to cover absences. When possible, the study subject should be scanned by the same sonographer at all visits.**

If any new sonographers are utilized during the 2693-CL-0302 study, PAREXEL must be informed.

Machine/Output Formats

Transvaginal Ultrasound (TVU):

- The recommended transducer(s) should range from 4.0 to 10.0 MHz however, it should be adjusted to operate at the highest clinically appropriate frequency.
- The machine should be capable of outputting images with measurements to the nearest 1.0 mm.
- The machine should be capable of transferring the exam in single frame standard DICOM format stored onto a local PACS or onto removable media (CD-ROM, DVD-ROM, USB removable hard drive). JPEG are also acceptable, but not recommended and can only be approved if DICOM not available.
- Only static images are acceptable (no video). In addition to static images, short (preferably 3-10 second long) cineloop images (saved in DICOM format) may be used for documenting pathology or difficult anatomy.

It is strongly preferred that all digital images be transferred to PAREXEL via electronic transfer (eTransfer).

If the above specifications are not possible, please notify PAREXEL via the site survey. Other options can be discussed and may be approved during imaging site qualification after discussion with Astellas.

Best Practices for Optimal Quality Ultrasound Imaging

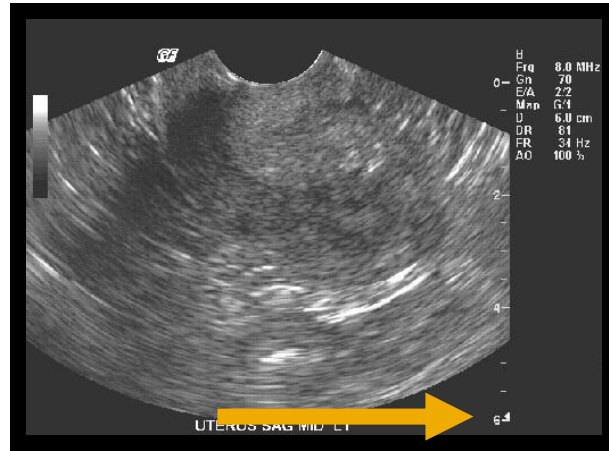
- Always utilize appropriate MHz transducer
- Watch focal zone: this should be adjusted as needed for different anatomy; single focus preferred
- Correct scanning depth should be utilized so visualized anatomy fills 2/3 of the screen
- Avoid wasted space; decrease depth if needed
- Avoid over magnification; decrease depth if needed
- Do not acquire split screen/dual images as part of the required views
- **Calibration bar must be present on all images at all times (typically visible near TGC curve)**
- Proper labeling of the anatomy, location, and plane on all images is **crucial** for independent review
- All pathology requires documentation in two planes

Common Image Quality Issues

Poor Focal Zone

The focal zone should be adjusted as needed to the area of interest.

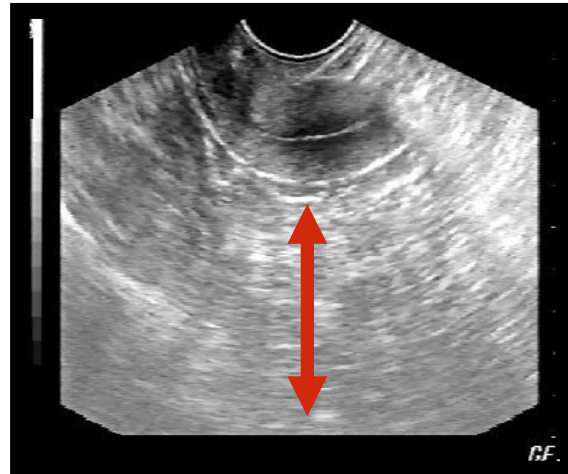
This example of focal zone (see yellow arrow for location) is too low and should be placed closer to the anatomy being visualized.



Inappropriate Scanning Depth

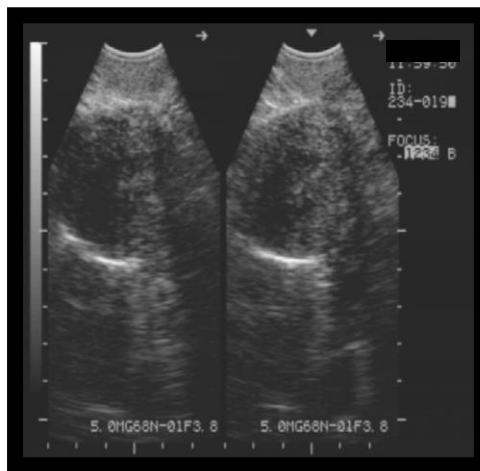
Correct scanning depth should be utilized so that anatomy fills approximately 2/3 of the screen.

Depth should be decreased as there is wasted space indicated by red arrow.



Split/dual Screen Images

Split/dual screen images may not be acquired as part of the required views



Missing Calibration bar

This is an example of what we need to see on all images. See ruler/scale on right hand side of image

Note: Calibration bar may be present in different locations due to machine manufacturer

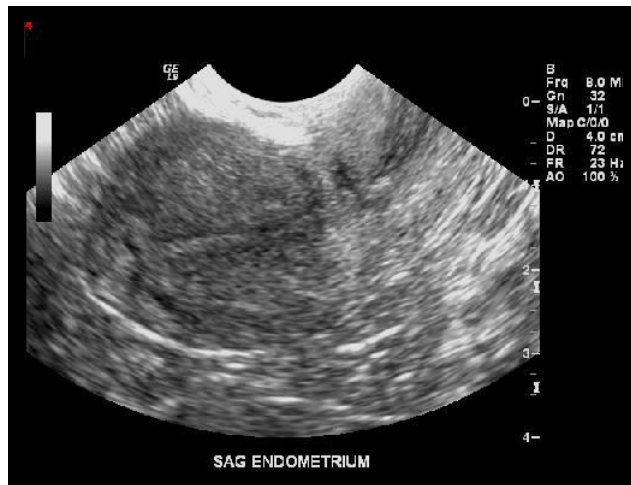


Image Labeling

Each image **must** contain:

1. Ten (10) digit subject ID: concatenated 5 digit site number and 5 digit subject number
2. Exam Date
3. **A calibration (scale) bar**
4. Anatomy being visualized (endometrium, uterus, etc.)
5. Location within body (right, left if appropriate)
6. Plane of view (sagittal / longitudinal, coronal / transverse)

Each image should **not** contain:

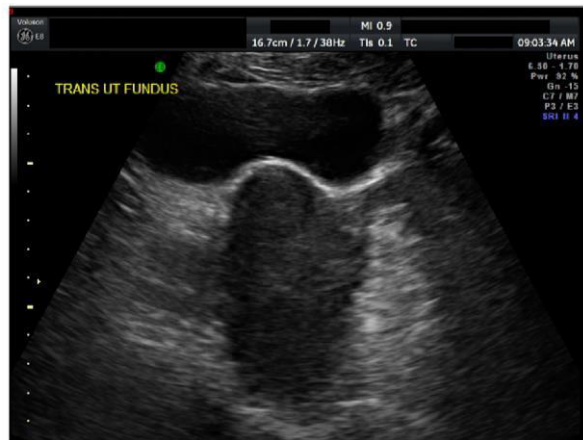
1. Measurements. Please note: if measurements must be obtained for site purposes a duplicate image WITHOUT measurements MUST be provided
2. Subject Names, Investigator Site Names, Medical Record Numbers, or other confidential details

Labeling Imaging is Critical

Always label:

- the anatomy (uterus, cervix, endometrium)
- location (right, left)
- plane (sagittal, coronal)
- every image/cine loop clip

Example here shows an appropriate label and label location. Recommended Image Labels/acceptable abbreviations are below for your reference



Recommended Image Labels and Acceptable Abbreviations

Sagittal / Longitudinal	sag / long
Transverse / Coronal	trn / cor
Uterus	Ut
Endometrium	Endo
Cervix	Cx
Lower Uterine Segment	Lus
Fundus	Fund
Body	Body
Right	RT
Left	LT
Parasagittal	Para
Anterior	Ant
Posterior	Post
Middle	Mid
Lateral	Lat
Medial	Med
Lower	Low
Fibroid	Fib
Cyst	Cyst

Note: All IMAGE LABELS SHOULD BE MADE directly ON THE IMAGE but AWAY FROM ANY ANATOMY.

TRANSVAGINAL ULTRASOUND (TVU)

TVU – Preparation and Important Reminders


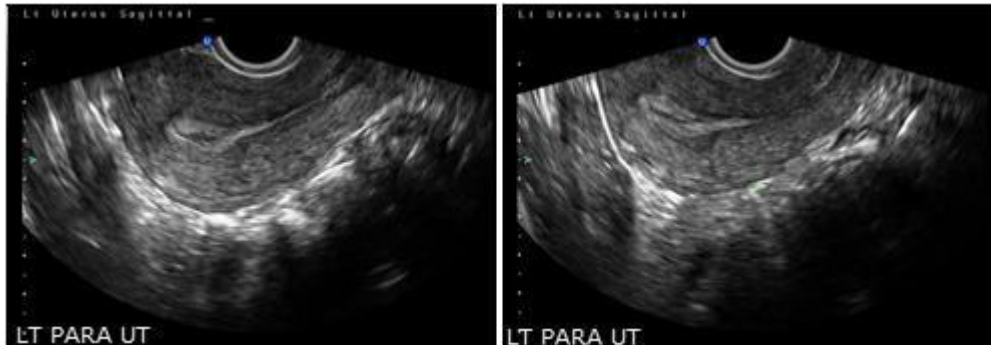
- Subject preparation: Bladder must be completely emptied prior to the transvaginal exam.
- The vaginal transducer is covered with gel and a cover with all air bubbles carefully excluded and additional gel placed on the outside of the probe cover.
- Calibration bar **must** be present on the image at all times.
- The image should be standardized so that the left side of the image monitor corresponds to the subject's right side when scanned in the transverse (coronal) plane and the posterior aspect of the uterus in the sagittal (longitudinal) plane. Probe should be in the notch up standardized position.
- The proper scanning depth must be utilized to ensure the region of interest is large enough to perform an adequate evaluation – anatomy being visualized should occupy 1/2 to 2/3 of the screen.
- The overall gain and time gain compensation (TGC) must be adjusted throughout the exam to optimally visualize the uterus, endometrium, ovaries and any pathology.
- The proper placement of the focal zone is vital to the proper resolution of the region of interest and should be adjusted throughout the exam as needed. Single focus preferred.
- Utilize the appropriate MHz transducer at all times.
- When scanning, demonstrate that all contours of the anatomy are visualized (i.e. sweep through the uterus until uterine tissue is not visualized).
- Ensure proper visualization (both planes) of any and all pathology including, but not limited to fibroids and/or endometrial polyps.
- Follow Image Acquisition Guidelines with regards to minimum required views and labeling of probe orientation (sagittal, coronal), location (right, left), anatomy (uterus, cervix, endometrium) and pathology (fibroid, mass).
- Split/dual screen should not be used for required images. However, additional images that include split screen images, power Doppler, color Doppler may be included if deemed pertinent to the subject.
- Images sent to PAREXEL should be **clear of any measurements or marks determined at the site**.
Note: if measurements must be obtained for site purposes a duplicate image without measurements must be provided




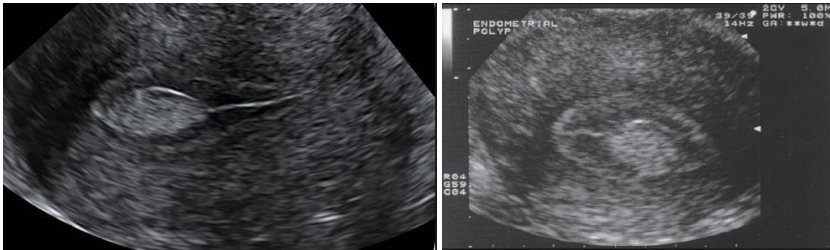
TVU - Image View Requirements

The following are minimum image view requirements

Required Views	Acceptable Abbreviations
<ul style="list-style-type: none"> 3 sagittal midline views including the endometrial stripe extending from the fundus to the lower uterine segment. Make sure to image entire endometrium from fundus to lower uterine segment Image the thickest portion of the endometrium If possible keep endometrium perpendicular to the field of view 	<p>sag mid endo</p>
2 views of the lower uterine segment into the cervical canal	<p>sag lus</p>
<ul style="list-style-type: none"> 2 left parasagittal views of the uterus Two different views representative of the uterine anatomy 	<p>LT para ut</p>
<ul style="list-style-type: none"> 2 right parasagittal views of the uterus Two different views representative of the uterine anatomy 	<p>RT para ut</p>
3 coronal views of the uterus <ul style="list-style-type: none"> Coronal uterus fundal Coronal uterus mid Coronal uterus low 	<p>cor ut fund cor ut mid cor ut low</p>

TVU - Representative Images

<p>Two right parasagittal uterus</p>	
<p>Two left parasagittal uterus</p>	

<p>Three sagittal midline uterus</p> <p>Three different views</p> <p>All should include endometrial stripe in its entirety and in its largest dimension</p>	
<p>Two views</p> <p>Lower Uterine Segment to cervix</p>	
<p>Three Coronal (transverse) uterus: fundal, mid, low</p>	
<p>Any extra images demonstrating pathology in two dimensions i.e. endometrial polyps</p>	

PAREXEL International Electronic Signature Page

This page is the manifestation of the electronic signature(s) used in compliance with PAREXEL International's electronic signature policies and procedures and in compliance with applicable regulations.

UserName: Collins, Elaine (colline)
Title: Associate Director, Scientific and Medical Serv, MEDICAL IMAGING
Date: Wednesday, 29 May 2019, 07:04 PM GMT Standard Time
Meaning: Document contents approved.

UserName: Blank, Heather (blankh)
Title: Senior Scientist, MEDICAL IMAGING
Date: Wednesday, 29 May 2019, 07:08 PM GMT Standard Time
Meaning: Document contents approved.

UserName: Francis, Kathryn (francik)
Title: Senior Project Manager, MEDICAL IMAGING
Date: Thursday, 30 May 2019, 12:37 PM GMT Standard Time
Meaning: Document contents approved.
